

The Use of a Retromammary Adipofascial Flap in Breast Augmentation for Patients with Thin Soft Tissue

Hyun Ho Han¹ · Kenneth K. Kim² · Kee Hoon Lee² · In-Beom Kim³ · Paik Kwon Lee⁴



Received: 21 May 2018 / Accepted: 14 August 2018

© Springer Science+Business Media, LLC, part of Springer Nature and International Society of Aesthetic Plastic Surgery 2018

Abstract

Background In patients with a thin soft tissue breast envelope, lower pole implant palpability is a postoperative sequela that concerns patients. Anatomically, the lower aspect of the breast near the inframammary fold lacks sufficient soft tissue to cover the breast implant after augmentation.

Methods A transareolar incision was made, and subcutaneous dissection was performed. The dissection first proceeded caudally to the lower aspect to the breast parenchyma. The dissection then changed direction and moved cephalad to the mid breast or nipple region. The fatty tissue and pectoralis muscle fascia were cut transversely at this level, and the dissection was reversed caudally in a subfascial plane to the new inframammary fold

region. This maneuver created a retromammary adipofascial flap.

Results A total of 368 breast augmentations were performed in 184 patients. Breast implants were inserted in the subfascial plane in 40 patients (21.7%) and in the subpectoral–subfascial plane in 144 patients (78.3%). A total of 368 breast implants were inserted, including 140 smooth cohesive silicone implants (38.0%), 2 textured round implants (0.5%), and 226 anatomic-type implants (61.5%). A cadaveric dissection revealed that a retromammary adipofascial flap measuring 3–4 mm in thickness can be acquired. Capsular contracture occurred in six breasts (1.7%).

Conclusions During breast augmentation, an inferiorly based retromammary adipofascial flap can be created to help cover the lower pole of the breast from implant palpability. This is helpful especially in patients with thin skin, hypoplastic breasts, or constricted breasts.

Level of Evidence IV This journal requires that authors assign a level of evidence to each article. For a full description of these Evidence-Based Medicine ratings, please refer to the Table of Contents or the online Instructions to Authors www.springer.com/00266.

This method in breast augmentation has been presented at the 2015 Korean Society of Plastic and Reconstructive Surgery Meeting in Seoul (13 Nov, 2015).

Electronic supplementary material The online version of this article (<https://doi.org/10.1007/s00266-018-1215-x>) contains supplementary material, which is available to authorized users.

✉ Paik Kwon Lee
prspklee@yahoo.com

¹ Department of Plastic Surgery, Asan Medical Center, University of Ulsan College of Medicine, Seoul, Korea

² Division of Plastic and Reconstructive Surgery, David Geffen School of Medicine at University of California, Los Angeles, CA, USA

³ Department of Anatomy, Catholic Institute for Applied Anatomy, College of Medicine, The Catholic University of Korea, Seoul, Korea

⁴ Apgugeong Avenue Plastic Surgery Clinic, Seil Bldg 6 fl., 11, Nonhyeon-ro 171-gil, Gangnam-gu, Seoul 06030, Korea

Keywords Retromammary adipofascial flap · Thin soft tissue · Autologous caudal breast augmentation · Caudal breast padding

Introduction

One significant aspect of breast augmentation is soft tissue coverage of the implant. Despite many advancements in the field of breast augmentation, the problem of inframammary or caudal breast region implant palpability

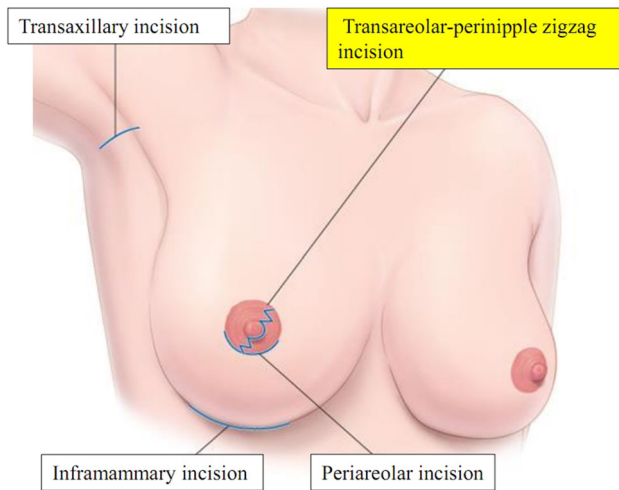


Fig. 1 Transareolar-perinipple (areolar omega) zigzag incision. This incision is useful to elevate the retromammary adipofascial flap

remains to be solved. Historically, the position of the breast implant pocket and soft tissue coverage have gone through many changes. In 1962, Cronin and Gerow [1] first introduced silicone implant insertion in the subglandular plane. Although it had the advantages of fast recovery and natural breast contour, the drawbacks included capsular contracture, downward migration of the implant, and visibility of implant edges [2]. In 1968, Dempsey and Latham [3] reduced the visibility of implants by placing them under the

subpectoral plane. However, undesirable implant displacement and/or distortion due to muscle actions occurred [4]. To overcome such drawbacks, Tebbetts [5], in 2006, described a dual-plane pocket technique that modified the subpectoral plane by changing the amount of submuscular and subglandular placement according to the patient's breast shape. Even with this technique, undesirable implant animation deformity and lower pole implant palpability could not be prevented [4, 5].

In 2000, Graf et al. [6, 7] introduced a subfascial plane approach that elevated the pectoralis major muscle fascia. This method yielded less capsular contracture compared with implantation using the subglandular plane, less undesirable implant animation compared with use of the submuscular plane, and a natural breast shape and fast recovery. Although breast augmentation through the subfascial plane has become popular [8–17], caudal region palpability remains an issue for patients with thin soft tissue.

A significant proportion of women who desire breast augmentation have thin soft tissue. Many also have hypoplastic and constricted breasts. In such cases, traditional subfascial or dual (partial subpectoral) plane augmentation cannot provide sufficient lower pole coverage. Therefore, the implant is palpable in patients with thin soft tissue. In addition, for patients with hypoplastic and constricted breasts, the aesthetic results are unsatisfactory

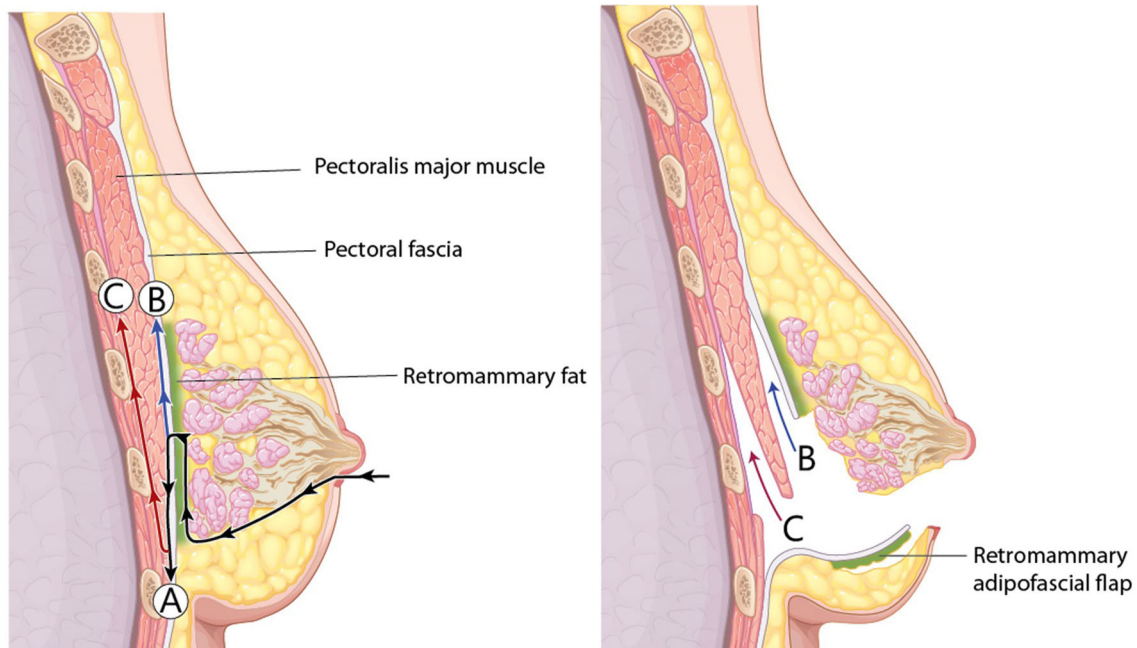


Fig. 2 Dissection planes. To lengthen the fascia in the lower pole, the pectoralis major muscle fascia with retromammary fat from the base of the breast parenchyma was elevated. **a** Inferior subfascial dissection to elevate the retromammary adipofascial flap including

the pectoralis major, rectus abdominis, external oblique, and serratus anterior muscle fasciae. **b** Upper subfascial dissection to achieve subfascial augmentation. **c** Subpectoral dissection in subpectoral–subfascial augmentation

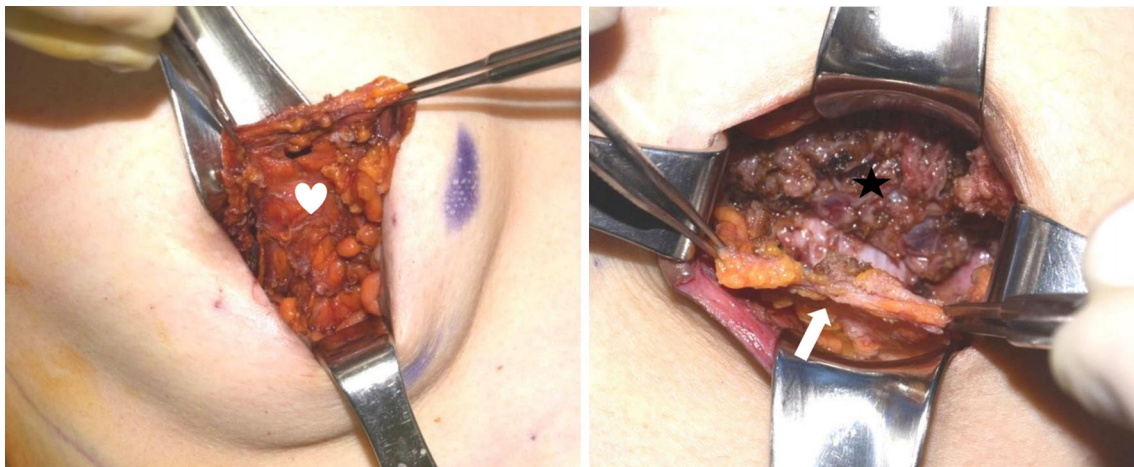


Fig. 3 Elevation of the retromammary adipofascial flap. Incorporation of retromammary fat with the fascia provides additional thickness to the flap. White heart and arrow: retromammary adipofascial flap, black star: pectoralis major muscle

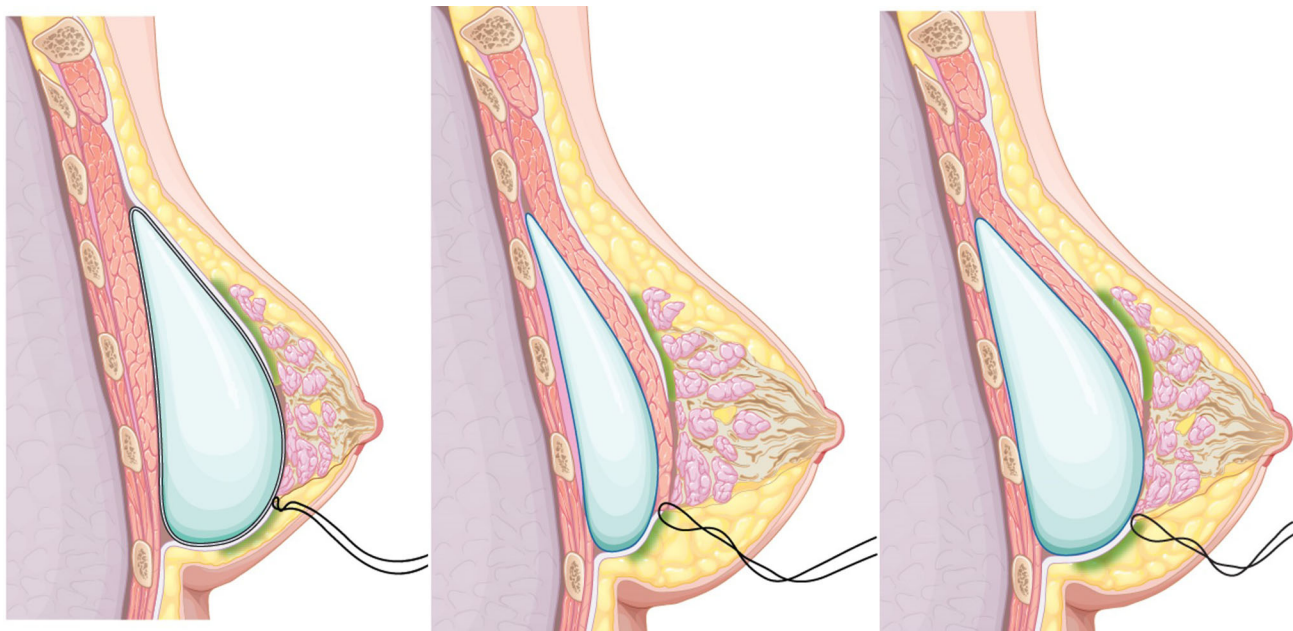


Fig. 4 Positioning of the implant. (Left) in subfascial pocket implant insertion, the proximal margin of the retromammary adipofascial flap and the lower edge of breast tissue are sutured. (Center) in subpectoral–subfascial pocket insertion of a small implant, the proximal margin of the retromammary adipofascial flap and the

lower portion of the pectoralis major muscle are sutured. (Right) in the case of subpectoral–subfascial pocket insertion of a large implant, the proximal margin of the retromammary adipofascial flap and the lower edge of breast tissue are sutured

because the skin and fascia of the lower pole are too tight. Therefore, the authors have introduced a retromammary adipofascial flap that utilizes retromammary fat under the breast tissue and fascia of the pectoralis major muscle to lengthen fascial coverage while transferring retromammary fat to increase soft tissue volume. This method could provide both fascial coverage and soft tissue padding of the lower pole of the breast. This can also be adopted in combination with a capsular flap or capsulofascial flap [18] in revision cases of implant palpability or rippling.

Materials and Methods

Between June 2012 and December 2015, 184 augmentation mammoplasties were performed using a retromammary adipofascial flap. Surgery was performed by the principal investigator (PKL). The incision was made using a transareolar-perinipple (areolar omega) zigzag approach [19]. Smooth cohesive silicone implants, textured round implants (in case of capsular contracture), and anatomic-type implants were used. If the pinch test of the breast

upper pole was ≥ 2.5 cm, subfascial plane insertion was selected. If the pinch test was < 2.5 cm, subpectoral–subfascial plane [13] insertion was selected. A retromammary adipofascial flap was used in every case.

Operation Technique

First, a transareolar-perinipple (areolar omega) zigzag incision [19] was made (Fig. 1). Subcutaneous dissection was performed just over the breast tissue in an inferomedial direction down to the caudal region of the breast tissue. From the caudal region of the breast tissue, the dissection changed direction and proceeded cephalad toward the level of the nipple or higher, depending on the needed length of fascia. The dissection plane was between the breast parenchyma and fatty tissue underneath. At the desired level of the breast, the fatty tissue and pectoralis muscle fascia were cut transversely, and the dissection was reversed caudally to the new inframammary fold (IMF) region (Figs. 2, 3). The dissection plane was now subfascial, creating an inferiorly based adipofascial flap. At the lower and lateral end of the pectoralis major muscle, the dissection was made to include fasciae of the rectus abdominis, external abdominal oblique, and serratus anterior muscles as one continuous fascial layer at the level of the new preoperatively determined IMF. To avoid injury to the lateral intercostal nerves, the lateral subfascial dissection was performed to the anterior axillary line. Medial dissection, either subpectorally or subfascially, was performed usually to the lateral border of the sternum, corresponding to 1.5 cm lateral to the midsternum.

In cases in which implants were inserted in a subfascial pocket, the caudal end of the breast tissue and the cut end of the retromammary adipofascial flap were sutured (Fig. 4, left). In subpectoral–subfascial pocket insertion of small implants, the caudal end of the pectoralis major muscle and cut end of the retromammary adipofascial flap were sutured (Fig. 4, center), whereas the caudal end of the breast tissue and cut end of the retromammary adipofascial flap were sutured when large implants were inserted (Fig. 4, right). Figure 5 shows the final appearance after implant insertion according to each plane. After subcutaneous approximation, skin closure was performed with either interrupted sutures or skin glue. After applying tape on the external breast surface, a light compressive elastic bandage and a foam sponge dressing were applied (Supplement Videos 1 and 2 demonstrating the subfascial pocket and subpectoral–subfascial pocket dissections, respectively).

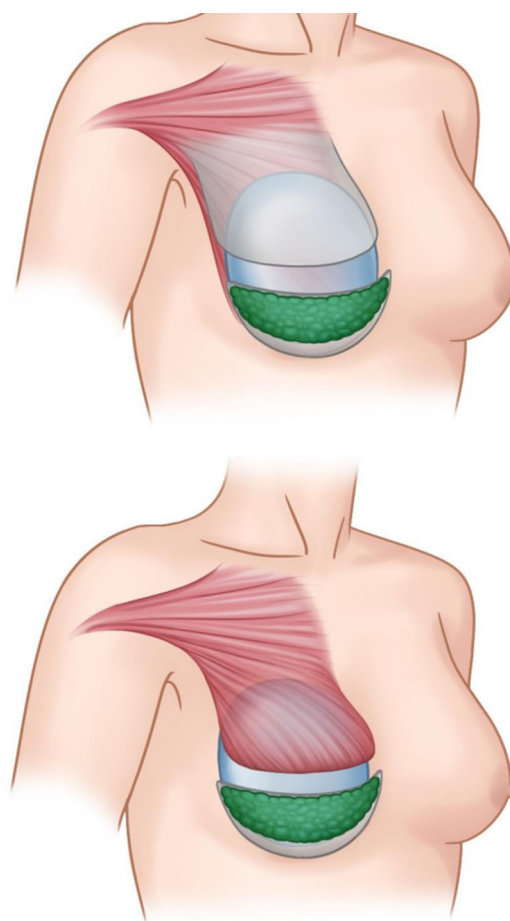


Fig. 5 Final appearance after implant insertion. (Above) subfascial pocket. (Below) subpectoral–subfascial pocket

Anatomical Study

A cadaveric dissection was performed to confirm retromammary fat and fascia mobilization. Both breasts of a 30-year-old female cadaver were dissected at the Institution of Applied Anatomy, in Seoul, South Korea. A retromammary adipofascial flap was elevated in one breast, and a vertical cut was made on the other. The distribution and location of retromammary adipofascial tissue were confirmed and documented.

Postoperative Follow-Up

Every patient was discharged on the day of the procedure. Patients were followed up for 13–60 months (mean: 21 months). Capsular contracture was evaluated between 1 and 2 years postoperatively, based on the Baker grading system [20].

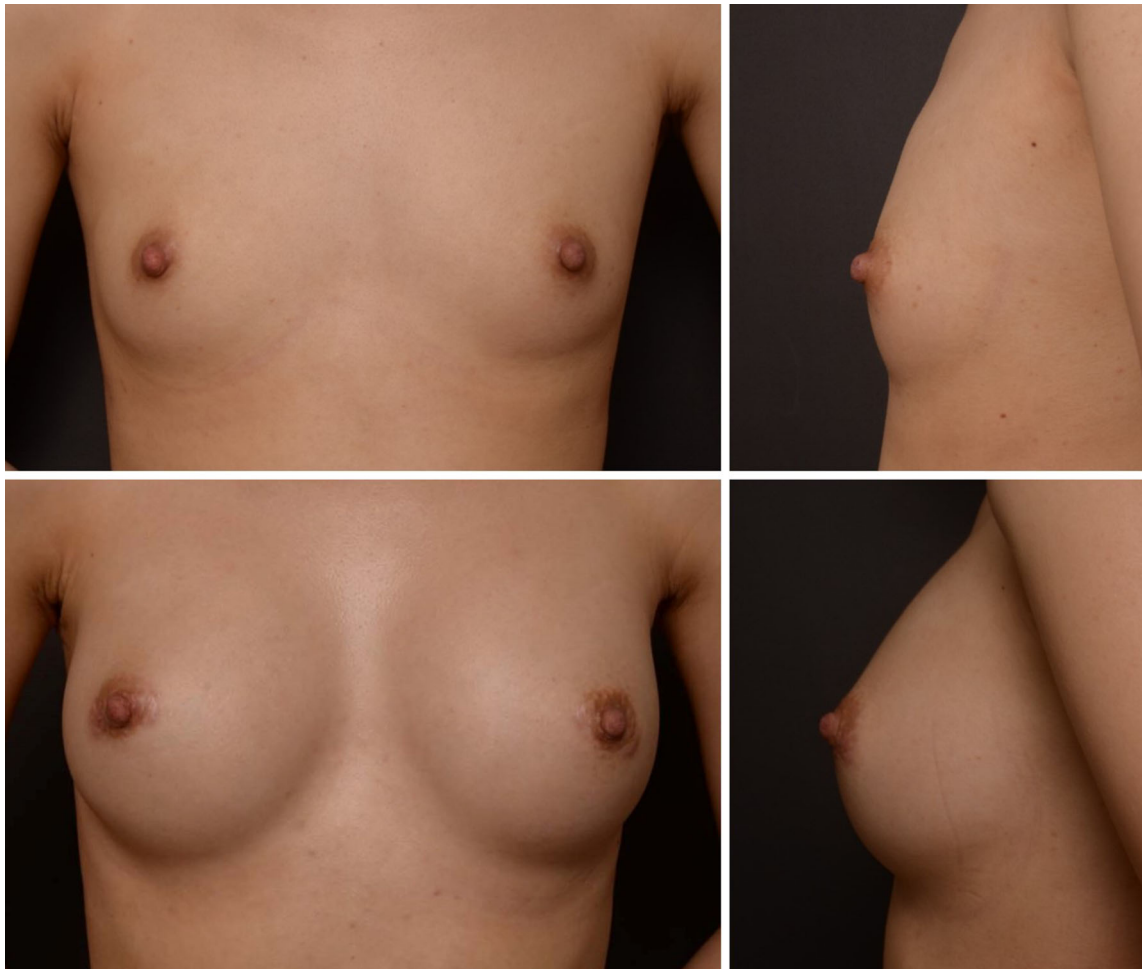


Fig. 6 Clinical result of a 26-year-old female patient. (Above) preoperative view. (Below) postoperative view at 1-year follow-up. Anatomic-type implants were inserted (right breast, 335 cc; left breast, 310 cc) in the subpectoral–subfascial pocket

Results

Between June 2012 and December 2015, a total of 184 patients received augmentation mammoplasty with a retromammary adipofascial flap. Results were satisfactory (Figs. 6, 7). This method was also applicable to tubular breasts (Fig. 8). There were 170 (92.4%) primary augmentation patients and 14 (7.6%) secondary augmentation patients. The group that underwent subfascial plane insertion comprised 40 (21.7%) patients, whereas 144 (78.3%) patients comprised the subpectoral–subfascial plane insertion group. Of 368 inserted implants, 140 (38.0%) were smooth cohesive silicone implants, 2 (0.5%) were round textured implants, and 226 (61.5%) were anatomic-type implants. The implant sizes ranged from 120 to 375 cc (median: 290 cc). The average operation time was 3 h 30 min (range: 2 h 30 min–4 h).

Anatomical Result

During cadaveric dissection, the authors elevated the adipofascial flap with 3–4 mm in thickness. After a vertical cut was made, examination revealed that retromammary fat volume progressively increased caudally toward the IMF (Fig. 9).

Complications

Complications were measured based on the findings in each breast. There were 21 surgical complications (5.7%) (Table 1). Clinically significant capsular contracture, defined as Baker grade III or IV [20, 21], occurred in six breasts (1.7%) in four patients. Among the six, five breasts (1.4%) had Baker class III and one breast (0.3%) had Baker class IV. Every incident occurred with the use of anatomic-type implants. Five patients (1.4%) showed implant palpability, and two patients (0.5%) showed bottoming out.

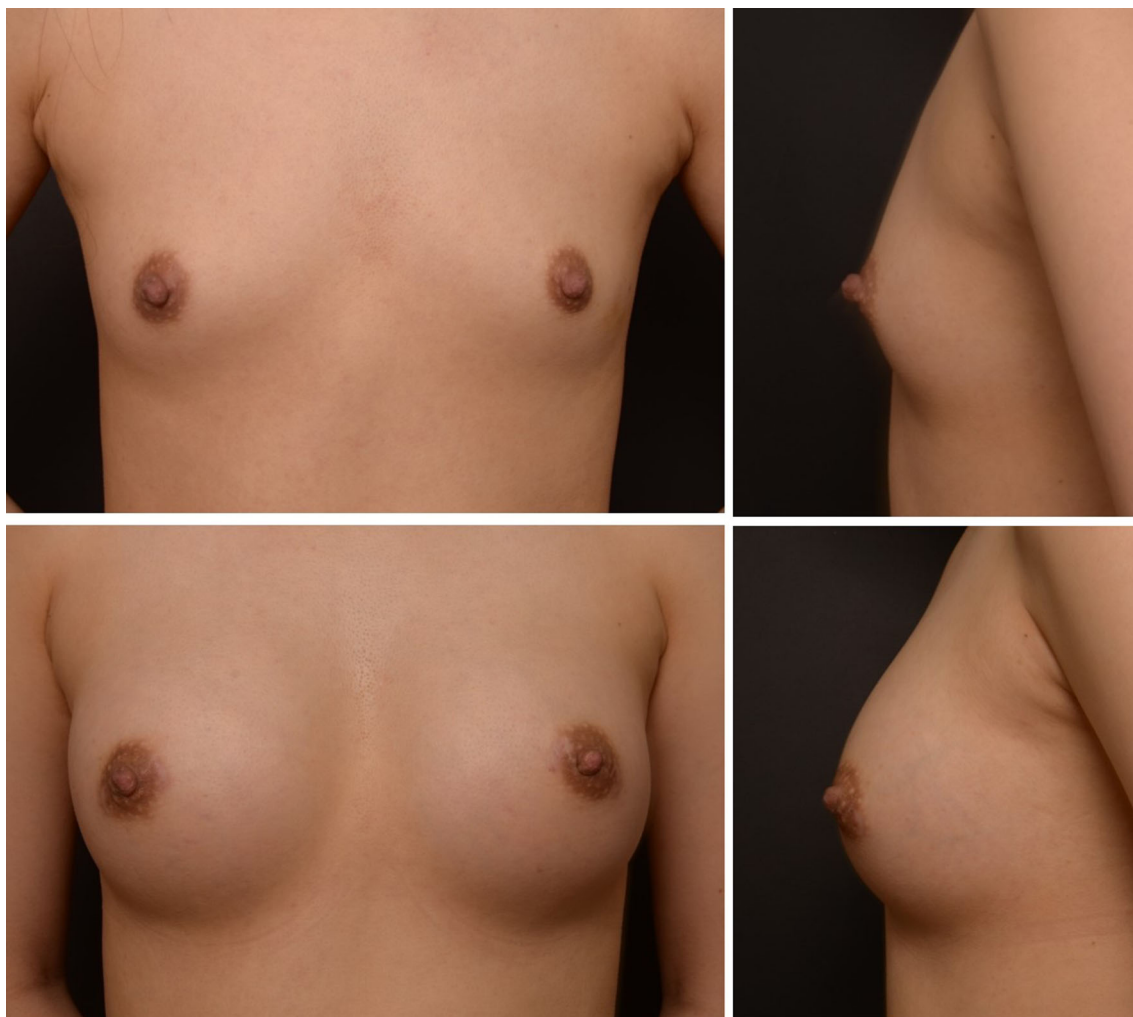


Fig. 7 Clinical result of a 30-year-old female patient. (Above) preoperative view. (Below) postoperative view at 1-year follow-up. Anatomic-type implants were inserted (right breast, 310 cc; left breast, 335 cc) in the subfascial pocket

Implant malpositioning where the implant migrated upwardly occurred in one patient (0.3%). Mild infection, which resolved with antibiotics alone, occurred in four patients (1.0%), and one patient (0.3%) developed hematoma (Table 1).

Discussion

Despite the number of advancements in breast augmentation, improving implant palpability at the caudal region of the breast in patients with thin soft tissue remains a challenge. In addition, constricted or hypoplastic breasts that have thin and tight soft tissue, commonly found in Asian women, further complicate the issue. In these patients, caudal expansion of the breast is crucial for allowing adequate tissue coverage of the implant and preventing a flattened caudal appearance. Excessive stretching of the

caudal region soft tissue could result in implant palpability, visibility, and rippling.

Other methods have been advocated to increase caudal region coverage of implants. The use of allogenic tissue (e.g., acellular dermal matrix) and autogenic tissue (e.g., fat grafting) has been proposed [22–28]. Acellular dermal matrices can be expensive and can cause infection and seroma formation. Fat grafting of the caudal region of the breast can lead to unpredictable absorption rates, fat necrosis, calcification, and donor site morbidity [28–31]. In secondary operations, the utility of a capsule flap is limited and difficult due to the stiff nature of scar tissue, especially when there is severe capsular contracture (Baker grade III or IV) [18].

Our technique utilizes the retromammary fascia and fat to support and provide extra padding for implant palpability. By mobilizing the lower half of the fascia and fat, we convert it to an adipofascial flap to increase surface area

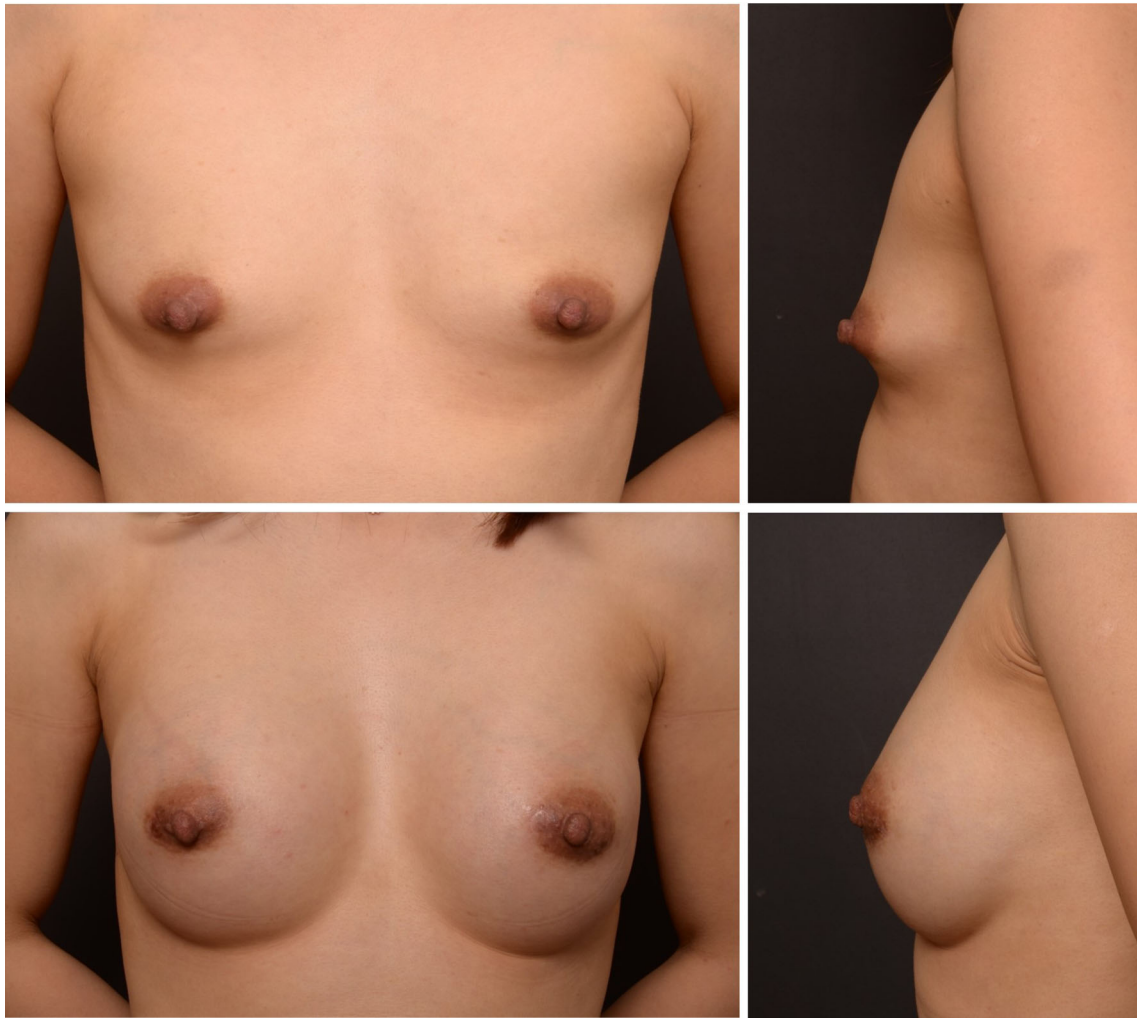


Fig. 8 Clinical result of a 32-year-old female patient. (Above) preoperative view. (Below) postoperative view at 1-year follow-up. Anatomic-type implants were inserted (right breast, 270 cc; left breast, 255 cc) in the subfascial pocket

and tissue coverage at the caudal region of the breast. On the contrary, performing complete subfascial elevation does not expand the caudal breast because the fascia at this region is relatively dense due to aggregation or overlap of the rectus abdominis fascia, external oblique fascia, and serratus anterior muscle fascia with the pectoralis muscle fascia. Therefore, unless these fasciae are cut longitudinally, the fascia would not expand radially. In addition, longitudinal fascial division will not cephalically increase the caudal region of the breast soft tissue envelope. Our technique has the advantage of being autologous and durable without causing donor site morbidity. We believe this may have a prophylactic effect in preventing bottoming out of the implant and can resolve problems such as implant palpability and rippling of the lower pole in primary and secondary breast augmentation.

After subfascial breast augmentation was first introduced by Graf et al. [6] in 2000, the use of pectoralis fascia

has gained popularity, but it has also created debates about its usefulness and durability. Studies have revealed that the thickness of the pectoralis major fascia ranges from 0.20 to 1.14 mm [32, 33]. The fasciae of the rectus abdominis, external oblique, and serratus anterior muscles were reported to be equal or thinner than the fascia of the pectoralis major muscle [31]. However, the overlapping structure enables surgeons to elevate and use the durable and relatively thick fascia as a caudal hinge of the adipofascial flap. Although a certain degree of difference might exist according to body mass index, retromammary fat elevation within the fascia could provide additional thickness. Compared with free fat grafting, this flap can provide sufficient stable coverage because of its vascularized nature. Furthermore, in secondary operations, this flap can provide a sling and soft tissue augmentation when accompanying a capsular flap.

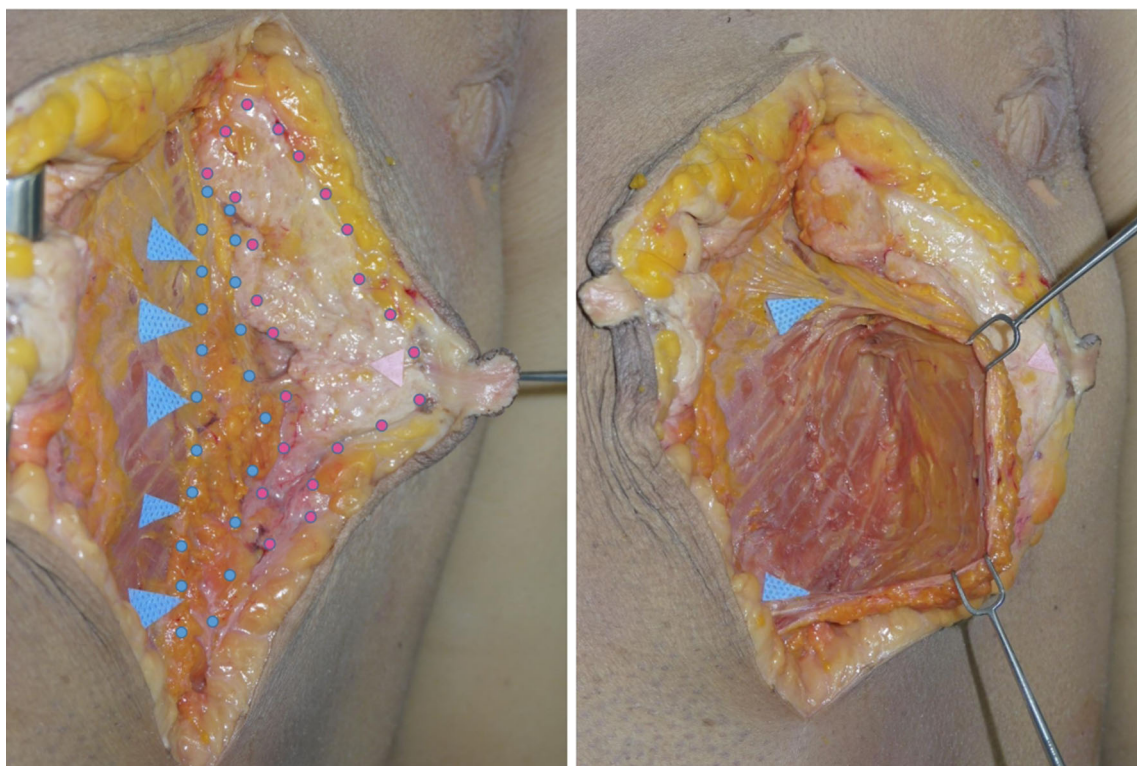


Fig. 9 Cadaveric dissection. (Left) a sagittal cut of cadaver breast revealed retromammary fat (indicated with blue arrows and dots) over the pectoralis major muscle and whitish breast parenchyma (indicated

with a pink arrow and dots). (Right) a dissection was performed in the retromammary adipofascial pocket

Table 1 Complication rate

Capsular contracture	
Baker I	360 (97.8%)
Baker II	2 (0.5%)
Baker III	5 (1.4%)
Baker IV	1 (0.3%)
Implant palpability	5 (1.4%)
Bottoming out	2 (0.5%)
Implant malposition	1 (0.3%)
Infection	4 (1.0%)
Hematoma or seroma	1 (0.3%)

The subfascial plane can be reached through transaxillary, inframammary, and periareolar approaches [6–17]. The periareolar approach facilitates elevation of the rectus abdominis, external abdominal oblique, and serratus anterior muscle fasciae in one sheet. This is because of its proximity to the entire breast circumferentially. However, the periareolar approach is technically difficult in patients with areolar diameters < 3.5 cm. Our areolar omega zig-zag incision technique allows for expansion of the areolar

opening so that surgery can be performed with ease even when the areolar diameter is small [19].

Capsular contracture is one of the most significant complications in breast augmentation. It has been postulated that breast glandular tissue manipulation increases the risk of capsular contracture. This may be due to microorganisms residing in glandular tissue [34–36]. However, dissecting in a plane between the subcutaneous tissue and the glandular tissue does not violate the breast glandular tissue, and thus, ductal tissue is not severed [19]. As such, the capsular contracture rate remained low (1.7%) in our series. We believe that meticulous hemostasis and avoidance of entering glandular tissue helped minimize capsular contracture.

In cases of narrow breast diameter, such as tuberous breasts and hypoplastic breasts, or when patients desire implants larger than their breast diameter, a longitudinal division of the adipofascial flap can be performed to expand the lower pole radially. It is important not to dissect caudally beyond the new IMF during fascial elevation in the lower portion of the breast. If it is unclear whether the new IMF has been violated, it is safer to fix the fascia to the muscle to prevent blunting of the IMF. Our technique is especially useful for tuberous breasts, as they can be corrected without any glandular manipulation, scoring, or

division (Fig. 6). The adipofascial flap that is raised from the mid to the upper breast region increases lower pole soft tissue coverage not only vertically but also radially. As mentioned above, if further radial expansion is needed, a vertical cut of the adipofascia can be performed. Thus, with no glandular cutting or scoring, we did not experience any increases in capsular contracture in tuberous breasts when compared with non-tuberous breasts.

This study has a number of limitations. First, there was no comparison of data with other procedures. The authors performed augmentation mammoplasty using only this technique, and there was a limit in setting and comparing a control group. Second, this technique is applicable only when using transareolar or periareolar incisions that the authors use. In these cases, nipple-areolar sensory preservation should be ensured. The transareolar-perinipple (areolar omega) zigzag incision in an oblique direction helps preserve the nipple sensation while making the scar less noticeable [19]. If the scar becomes wider or brighter, it can be visible, but it can be easily resolved by a tattoo. The third is the short follow-up period. An average of 2 years is not enough to assess complications such as capsular contracture.

Conclusion

The application of a retromammary adipofascial flap is an effective method of producing natural breast shape and providing additional soft tissue to the caudal breast region. Autologous pedicled fasciae and retromammary fat structurally support and increase volume to expand and pad the caudal breast. Therefore, rippling and implant palpability of the caudal region are improved. This is especially useful in patients with thin soft tissue with constricted, tight, or hypoplastic breasts.

Compliance with Ethical Standards

Conflict of interest The authors declare that they have no conflict of interest and no financial support.

Ethical Approval This study was conducted in accordance with the principles of the Declaration of Helsinki, and all patients provided written informed consent prior to enrollment.

References

- Cronin TD, Gerow JF (1963) Augmentation mammoplasty; a new "natural feel" prosthesis. Paper presented at: transactions of the third international congress of plastic surgery, October 13–18. Excerpta Medica Foundation, Amsterdam
- Vazquez B, Given KS, Houston GC (1987) Breast augmentation: a review of subglandular and submuscular implantation. *Aesthet Plast Surg* 11:101–105
- Dempsey WC, Latham WD (1968) Subpectoral implants in augmentation mammoplasty. Preliminary report. *Plast Reconstr Surg* 42:515–521
- Spear SL, Schwartz J, Dayan JH, Clemens MW (2009) Outcome assessment of breast distortion following submuscular breast augmentation. *Aesthet Plast Surg* 33:44–48
- Tebbetts JB (2006) Dual plane breast augmentation: optimizing implant-soft-tissue relationships in a wide range of breast types. *Plast Reconstr Surg* 118:81S–98S
- Graf RM, Bernardes A, Auersvald A, Damasio RC (2000) Subfascial endoscopic transaxillary augmentation mammoplasty. *Aesthet Plast Surg* 24:216–220
- Graf RM, Bernardes A, Rippel R, Araujo LR, Damasio RC, Auersvald A (2003) Subfascial breast implant: a new procedure. *Plast Reconstr Surg* 111:904–908
- Goes JC, Landecker A (2003) Optimizing outcomes in breast augmentation: seven years of experience with the subfascial plane. *Aesthet Plast Surg* 27:178–184
- Serra-Renom J, Garrido MF, Yoon T (2005) Augmentation mammoplasty with anatomic soft, cohesive silicone implant using the transaxillary approach at a subfascial level with endoscopic assistance. *Plast Reconstr Surg* 116:640–645
- Munhoz AM, Fells K, Arruda E et al (2006) Subfascial transaxillary breast augmentation without endoscopic assistance: technical aspects and outcome. *Aesthet Plast Surg* 30:503–512
- Siclován HR, Jomah JA (2008) Advantages and outcomes in subfascial breast augmentation: a two-year review of experience. *Aesthet Plast Surg* 32:426–431
- Stoff-Khalili MA, Scholze R, Morgan WR, Metcalf JD (2004) Subfascial periareolar augmentation mammoplasty. *Plast Reconstr Surg* 114:1280–1288
- Lee JH, Lee PK, Oh DY, Rhie JW, Ahn ST (2012) Subpectoral-subfascial breast augmentation for thin-skinned patients. *Aesthet Plast Surg* 36:115–121
- Hunstad JP, Webb LS (2010) Subfascial breast augmentation: a comprehensive experience. *Aesthet Plast Surg* 34:365–373
- Tijerina VN, Saenz RA, Garcia-Guerrero J (2010) Experience of 1000 cases on subfascial breast augmentation. *Aesthet Plast Surg* 34:16–22
- Brown T (2012) Subfascial breast augmentation: is there any advantage over the submammary plane? *Aesthet Plast Surg* 36:566–569
- Aygit AC, Basaran K, Mercan ES (2013) Transaxillary totally subfascial breast augmentation with anatomical breast implants: review of 27 cases. *Plast Reconstr Surg* 131:1149–1156
- Yoo G, Lee PK (2010) Capsular flaps for the management of malpositioned implants after augmentation mammoplasty. *Aesthet Plast Surg* 34:111–115
- Han HH, Kim KK, Lee KH et al (2015) Transareolar-perinipple (areolar omega) zigzag incision for augmentation mammoplasty. *Plast Reconstr Surg* 135:517e–525e
- Spear SL, Baker JL Jr. (1995) Classification of capsular contracture after prosthetic breast reconstruction. *Plast Reconstr Surg* 96:1119–1123
- Hester TR Jr, Ghazi BH, Moyer HR, Nahai FR, Wilton M, Stokes L (2012) Use of dermal matrix to prevent capsular contracture in aesthetic breast surgery. *Plast Reconstr Surg* 130:126S–136S
- Kaufman D (2012) Pocket reinforcement using acellular dermal matrices in revisionary breast augmentation. *Clin Plast Surg* 39:137–148
- Hartzell TL, Taghinia AH, Chang J, Lin SJ, Slavin SA (2010) The use of human acellular dermal matrix for the correction of secondary deformities after breast augmentation: results and costs. *Plast Reconstr Surg* 126:1711–1720

24. Mofid MM, Singh NK (2009) Pocket conversion made easy: a simple technique using alloderm to convert subglandular breast implants to the dual-plane position. *Aesthet Surg J* 29:12–18
25. Maxwell GP, Gabriel A (2014) Acellular dermal matrix for reoperative breast augmentation. *Plast Reconstr Surg* 134:932–938
26. Pozner JN, White JB, Newman MI (2013) Use of porcine acellular dermal matrix in revisionary cosmetic breast augmentation. *Aesthet Surg J* 33:681–690
27. Separ SL, Sinkin JC, Al-Attar A (2013) Porcine acellular dermal matrix (strattice) in primary and revision cosmetic breast surgery. *Plast Reconstr Surg* 131:1140–1148
28. Spear SL, Wilson HB, Lockwood MD (2005) Fat injection to correct contour deformities in the reconstructed breast. *Plast Reconstr Surg* 116:1300–1305
29. Bircoll M (1987) Cosmetic breast augmentation utilizing autologous fat and liposuction techniques. *Plast Reconstr Surg* 79:267–271
30. Zheng DN, Li QF, Lei H et al (2008) Autologous fat grafting to the breast for cosmetic enhancement: experience in 66 patients with long-term follow-up. *J Plast Reconstr Aesthet Surg* 61:792–798
31. Teimourian B (1986) Repair of soft-tissue contour deficit by means of semiliquid fat graft. *Plast Reconstr Surg* 78:123–124
32. Jinde L, Jianlianq S, Xiaoping C et al (2006) Anatomy and clinical significance of pectoral fascia. *Plast Reconstr Surg* 118:1557–1560
33. Stecco A, Masiero S, Macchi V, Stecco C, Porzionato A, De Caro R (2009) The pectoral fascia: anatomical and histological study. *J Bodyw Mov Ther* 13:255–261
34. Handel N, Jensen JA, Black Q, Waisman JR, Silverstein MJ (1995) The fate of breast implants: a critical analysis of complications and outcomes. *Plast Reconstr Surg* 96:1521–1533
35. Wixtrom RN, Stutman RL, Burke RM, Mahoney AK, Codner MA (2012) Risk of breast implant bacterial contamination from endogenous breast flora, prevention with nipple shields, and implications for biofilm formation. *Aesthet Surg J* 32:956–963
36. Jennings DA, Morykwas MJ, Burns WW, Crook ME, Hudson WP, Argenta LC (1991) In vitro adhesion of endogeneous skin microorganisms to breast prostheses. *Ann Plast Surg* 27:216–220