



# Correction of Asian Short Nose with Lower Lateral Cartilage Repositioning and Ear Cartilage Grafting

Jin Suk Byun, MD, PhD\*  
Kenneth K. Kim, MD,  
FACS†,‡

**Background:** Asians with short nose lack the cartilage needed to extend the length of the nose. A rhinoplasty technique using lower lateral cartilage (LLC) repositioning and ear cartilage grafting allows for sufficient nasal lengthening and nasal tip mobility in the correction of short nose in Asians.

**Methods:** Short nose was classified into 3 subtypes: type I, II, or III. During LLC repositioning, the LLC was separated from surrounding retaining structures, except at the footplate. The LLC was approximated medially and advanced with a Medpor strut. A silicone dorsal implant was inserted to suit the newly projected nasal tip. An ear cartilage onlay graft or ear cartilage extension graft was applied to further project and enhance the nasal tip and columella.

**Results:** Of the 854 primary rhinoplasty procedures performed on Asian patients between January 2008 and December 2011, 295 were performed on patients with short nose. LLC repositioning and ear cartilage onlay grafting were performed on 228 patients. LLC repositioning and ear cartilage extension grafting with or without ear cartilage onlay grafting were performed on 67 patients. Short nasal tip, alar retraction, and columellar retraction were corrected. Wound dehiscence with marginal necrosis occurred in 7 patients. One patient developed nasal infection.

**Conclusions:** LLC repositioning and ear cartilage grafting aid in the correction of short nose in Asians. With LLC repositioning and ear cartilage grafting, the nasal tip can be positioned in accordance with the patient's anatomic limits. The entire nasal tip and columella can be lengthened, while the tip maintains its mobility. (*Plast Reconstr Surg Glob Open* 2013;1:e45; doi: 10.1097/GOX.0b013e3182a85b29; Published online 23 August 2013.)

From the \*BS Aesthetic Clinic, Daegu, Korea; †Dream Medical Group, Los Angeles, Calif.; and ‡Division of Plastic and Reconstructive Surgery, David Geffen School of Medicine at University of California, Los Angeles, Calif.

Received for publication April 10, 2013; accepted July 18, 2013.

Presented at the Seoul Rhinoplasty Forum in Seoul, South Korea, June 16, 2012.

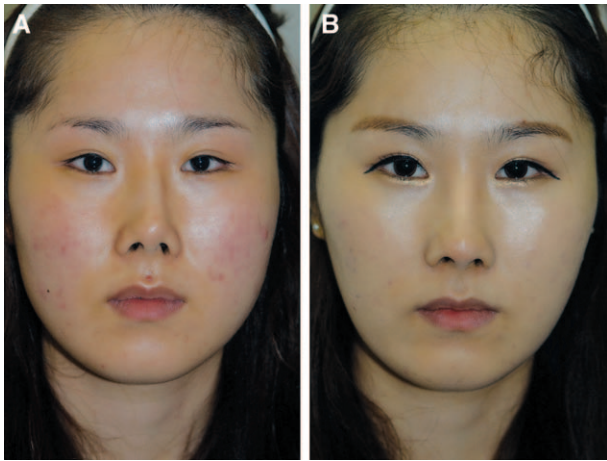
Copyright © 2013 The Authors. Published by Lippincott Williams & Wilkins on behalf of The American Society of Plastic Surgeons. PRS Global Open is a publication of the American Society of Plastic Surgeons. This is an open-access article distributed under the terms of the Creative Commons Attribution-NonCommercial-NoDerivatives 3.0 License, where it is permissible to download and share the work provided it is properly cited. The work cannot be changed in any way or used commercially.

DOI: 10.1097/GOX.0b013e3182a85b29

Compared with other ethnicities, Asians have the highest prevalence of short nose.<sup>1,2</sup> Short nose is difficult to correct because the underlying framework of the nose is limited in its ability to withstand the opposing contractile force from the nasal skin envelope. Compared with whites, Asians tend to have a smaller amount of nasal cartilage, and the cartilage is much less firm. Asians also tend

**Disclosure:** The authors have no financial interest to declare in relation to the content of this article. The Article Processing Charge was paid for by the authors.

Supplemental digital content is available for this article. Clickable URL citations appear in the text.



**Fig. 1.** A, Patient who underwent short nose correction with septal extension, septal cartilage grafting, and dorsal silicone implantation. The patient shows persistent alar retraction with excessive nostril show. B, Same patient underwent revision rhinoplasty with lower lateral cartilage repositioning, ear cartilage grafting, Medpor columellar strut grafting, and dorsal silicone implantation. Correction of alar retraction and excess nostril show can be seen.

to have thicker and less pliable skin. These factors contribute to the difficulties of nasal augmentation, especially proper tip projection.

To overcome such conditions, septal cartilage extension grafts and costal cartilage grafts have been used to provide adequate support for the nasal tip.<sup>3-5</sup> However, if the amount of pressure applied to heighten the tip of the nose exceeds the pliability of the skin envelope, only the region of the skin that is most pliable (the central tip) and the focal region with the highest amount of tension (the dorsum) expand. Therefore, only the central component of the nose is altered to any significant degree, whereas the lateral component of the nasal tip remains in its original position. The lateral ala appears retracted while the central nasal tip appears overemphasized (Fig. 1A), resulting in an unnatural and sharp appearance of the nose.

We believe that short nose should be aesthetically restructured within the limits of skin expansion in individual patients. In addition, the entire lower aspect of the nose must be lengthened to achieve a harmonious and natural appearance. This can be accomplished by releasing the retaining components of the lower lateral cartilage (LLC). We devised a technique that freely mobilizes the LLC (except at the footplate) and then repositions it at the desired location to effectively correct short nose.

**PATIENTS AND METHODS**

The authors identified 3 conditions of short nose: short nasal tip, short alar rim (alar retraction), and short columellar base (columellar retraction). Short

**Table 1. Categorization and Probability of the Short Nose Types (n = 295)\***

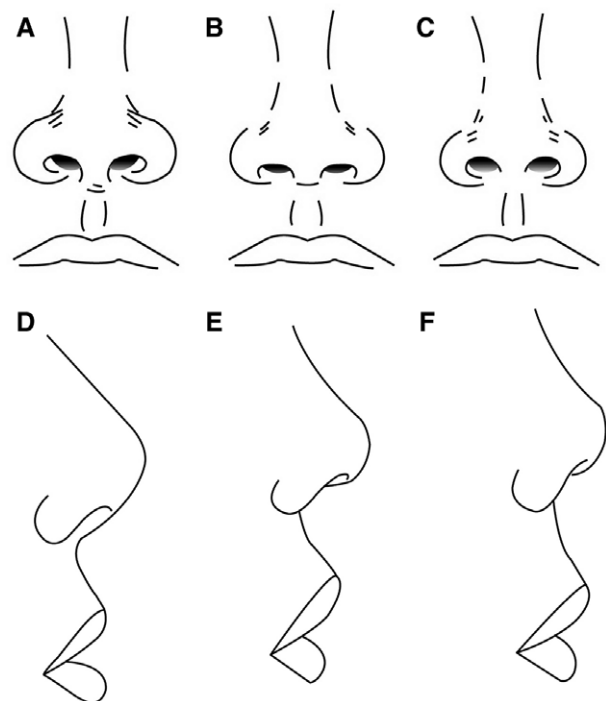
Short Nose Subtype	Criteria	% (Cases)
Type I	Short nasal tip, alar retraction	63.4 (187)
Type II	Short nasal tip, columellar retraction	20.7 (61)
Type III	Alar retraction, columellar retraction	15.9 (47)

\*The case number consists of the total short nose cases performed.

nose was diagnosed when 2 or more identified short nose conditions existed in a patient. The combinations of short nose conditions were then classified into 3 subtypes: type I, type II, or type III (Table 1).

Short nose in patients was classified as type I when the nasal tip was short and alar retraction was seen while the position of the columella was within normal range. Short nose was classified as type II when alar retraction was not present, but the nasal tip was short and the columella was retracted. Short noses with a short nasal tip and retracted alar rim and columellar base were classified as type III (Fig. 2).

Between January 2008 and December 2011, 854 Asian patients (mean age, 28.2 y; 735 females, 129 males) underwent primary rhinoplasty. Among them, 295 patients were diagnosed with short nose



**Fig. 2.** Three classified types of short nose at frontal view (A–C) and side view (D–F). A and D, Marginal-type short nose with short nasal tip and alar retraction. B and E, Basal-type short nose with short nasal tip and columellar retraction. C and F, Severe short nose with short nasal tip, columellar retraction, and alar retraction.

with the above criteria. These patients were followed up for 6 months to 5 years (mean, 3.8 y).

**Surgical Procedure**

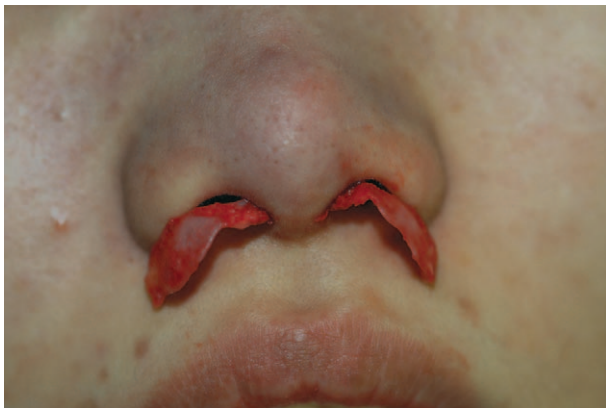**Endonasal Incision.** Bilateral marginal incisions were made to separate the nasal skin envelope from the underlying structures of the LLC, upper lateral cartilage, and nasal bone. Supraperichondreal cartilaginous dissection was performed while subperiosteal bony dissection was performed.

**Cartilage Isolation.** To isolate the LLC, the caudal ends of the LLC and vestibular skin were dissected starting from the domal region. The dissection

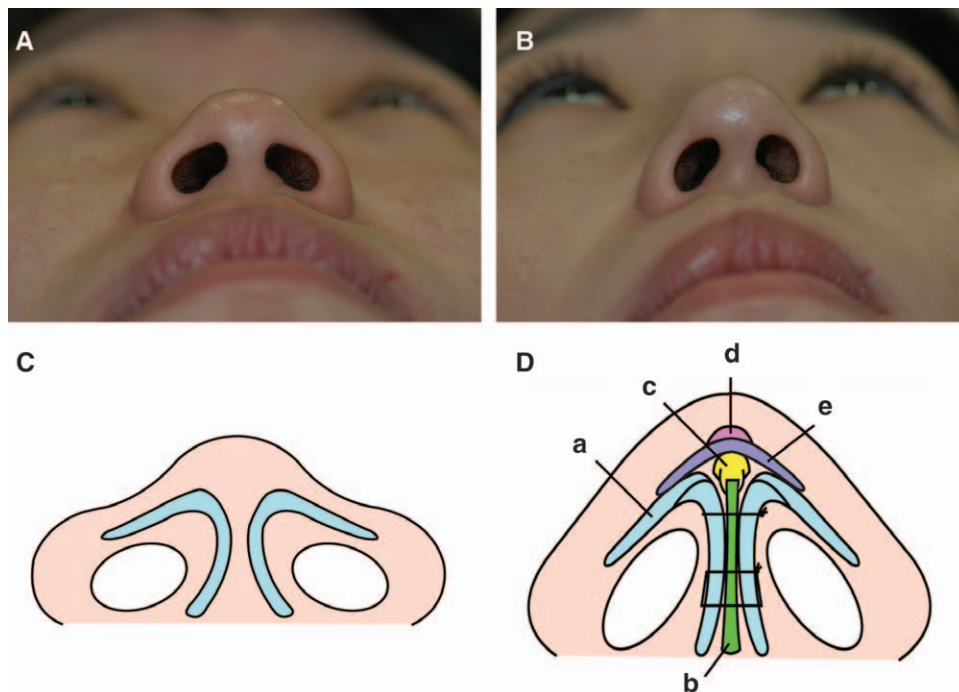
proceeded directly cephalad in a plane under the LLC, yet above the vestibular skin to the scroll region. The dissection then proceeded to the hinge complex (lateral edge of the lateral crura) in this plane. At the hinge complex, the LLC was released from its retaining components (ie, pyriform ligament, superficial musculoaponeurotic system, and perichondrium) and the dissection proceeded back medially and cephalad, releasing the rest of the scroll. The middle and medial crura were separated from the membranous septum and the nasal mucosa up to the footplate (Fig. 3).

**Tip Projection.** A Medpor strut (20 mm in length, 2.5–3.0 mm in width, and 0.85 mm in thickness) was inserted into the space between the medial crura of the LLC and transfixed with horizontal mattress sutures using 6-0 nylon just above the footplate. Care was taken so that the Medpor strut was buried within the medial crura and that its edges were not exposed. Another transfixation suture was placed at the medial corner of the domal angle. Bringing the medial crura to the columellar strut lengthened the columella and simultaneously extended the nasal tip (Fig. 4). The lower end of the Medpor strut did not reach the anterior nasal spine. The higher end of the strut was trimmed so that it reached the undersurface of the skin of the nasal tip without any tension.

**Dorsum Augmentation.** A silicone implant was trimmed to fit the contour of the patient’s dorsal



**Fig. 3.** Isolation of the lower lateral cartilage. Release of the lower lateral cartilage after dissection.

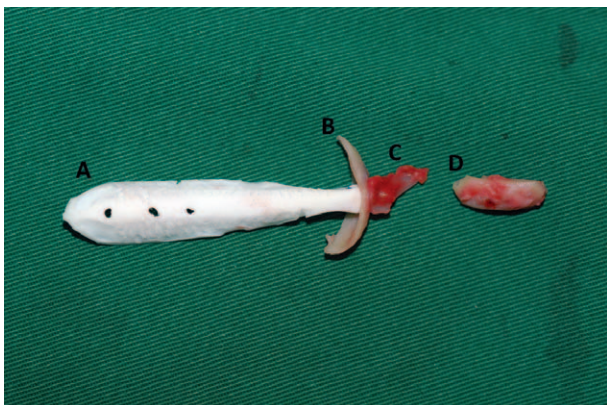


**Fig. 4.** Basal view of the shape of the nostrils, contour of the alar margins, and length of the nasal tip before (A) and after (B) alar cartilage repositioning. Illustration of the basal view before (C) and after (D) cartilage modification and graft placement. a, Lower lateral cartilage; b, Medpor strut; c, silicone implant; d, vertical cartilage graft; e, horizontal cartilage graft.

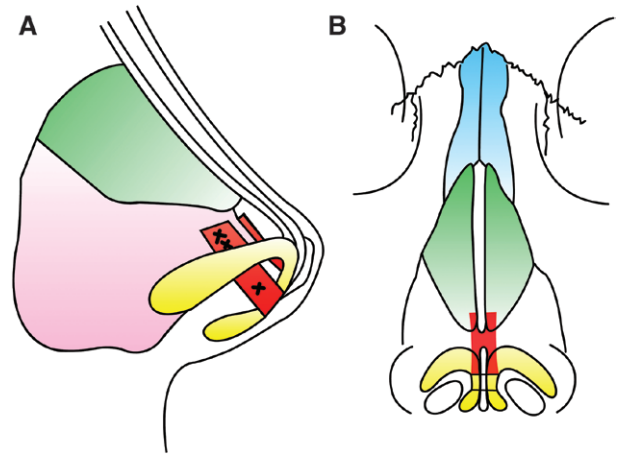


surface. The tip portion was carved thinner and smaller than the middorsal portion. The neck of the dorsal implant (between the tip and the middorsum) was carved especially thin and narrow so that the tip portion could easily bend and move. The height of the dorsum was adjusted according to the newly formed nasal tip with a slight concave contour in females and a straight profile in males. The starting point of the nasal implant was usually at the midpoint between the eyebrow and the pupil. A no. 11 blade was used to create a space on the undersurface of the silicone tip region. The upper end of the Medpor strut was inserted by a tongue-and-groove fashion into the silicone undersurface and was sutured with 6-0 nylon.

**Tip Contouring.** Changing the shape of the nostrils, contouring the alar lobules, and lengthening the nasal tip and alar margins were easily achieved by LLC repositioning (Fig. 5). Completely freeing and repositioning the LLC lengthened the nasal tip and significantly improved alar contour. Horizontal and vertical cartilage grafts were placed on the dorsal implant (Fig. 5). The edges of these grafts were carefully beveled to prevent graft demarcation show. The horizontal graft made of symba cartilage was used to provide structural support to the tip and alar margin and to improve the contour of the tip and alar lobule. In some patients with an excess amount of LLC, the LLC was trimmed so that the cephalic portion of the LLC was used in the vertical component of the tip graft. In patients without excess LLC, a conchal cartilage graft was used in the vertical component of the tip graft. The vertical component was positioned to slightly project the columella and prevent direct contact of the Medpor implant with the nasal skin envelope. Placing a barrier between the Medpor implant and skin prevented extrusion of the Medpor implant.



**Fig. 5.** Above view of carved silicone implant (A) with symba cartilage graft (B) horizontally placed on the tip of silicone implant and cephalic trim of the lower lateral cartilage graft (C) vertically placed. Extra auricular graft (D) may be used as an additive graft on the tip or columella for further projection.



**Fig. 6.** A, Side view diagram of the extension graft. B, Front view diagram of the extension graft (red).

**Ear Cartilage Onlay Grafting.** Additional ear cartilage onlay grafts were placed when nasal tip deficiency or alar retraction was still present after LLC repositioning. If the nasal tip was deficient without alar retraction, then a simple, beveled, round umbrella graft was placed on top of the tip. However, if the short nasal tip persisted with alar retraction (as in certain cases of type II or III short nose), then a more transversely designed umbrella graft was placed on top of the tip and alar region to extend both the tip and the alar rim.

**Ear Cartilage Extension Grafting.** In addition to LLC repositioning and ear cartilage onlay grafting, ear cartilage extension grafting was used to treat patients with significantly retracted columella. Twenty out of 61 patients with type II short nose and all of type III short noses exhibited significantly retracted columella and received additional ear cartilage extension grafting. Two strips of ear cartilage were overlapped and fixed at the middle region to create an “X” shape (Fig. 6). One end of the cartilage was fixed at the caudal end of the septal cartilage. The other ends of the extension graft were attached to the medial crura to extend them caudally. When the medial crura were repositioned caudally, the freed middle crura and lateral crura also moved caudally.

## RESULTS

Between January 2008 and December 2011, 854 primary rhinoplasty procedures were performed on Asian patients. Two hundred ninety-five or about one-third of these were short nose correction surgeries performed in patients diagnosed with short nose. Short nose surgery was performed on patients over 16 years old. The age groups of patients were as follows: 33 patients (11.2%) were 16–20 years old, 173 patients (58.6%) were 21–30 years old, and 52

**Table 2. Patient Demographics: Short Nose Correction, 2008 to 2011 (n = 854)\***

Characteristics	Total Patients N = 854*	Short Nose Cases N = 295**
Gender		
Female, % (n)	84.9 (725)	85.8 (253)
Male, % (n)	15.1 (129)	14.2 (42)
Age, y		
16–20		11.2 (33)
21–30		58.5 (173)
31–40		17.5 (52)

\*The case number consists of the total rhinoplasty performed.

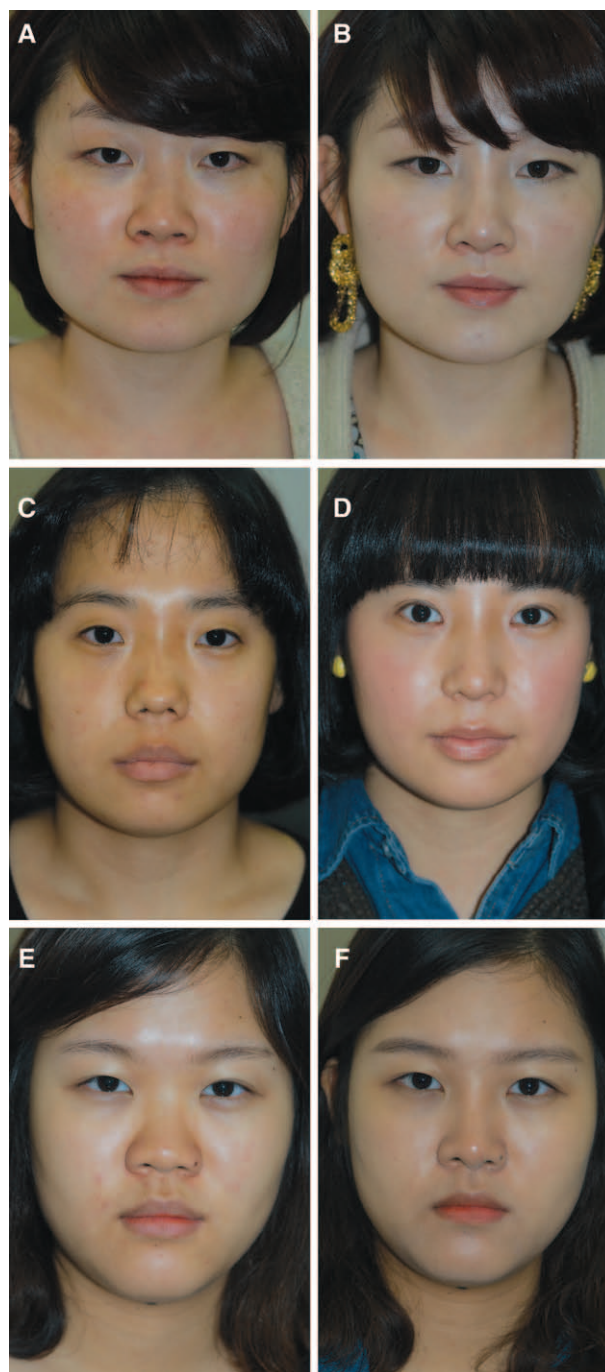\*\*The case number consists of the total short nose cases performed.

patients (17.6%) were 31–40 years old. Therefore, the majority of patients who underwent correction of short nose were from the age groups below 30 years. One hundred twenty-nine procedures (15.1%) of primary rhinoplasty were performed on males. Among those, 42 (32.5%) were performed on patients with short nose. Seven hundred twenty-five primary rhinoplasty procedures were performed on females. Among those, 253 (34.8%) were performed on patients with short nose (Table 2).

Among short nose cases, 187 (63.4%) were of type I, 61 (20.7%) were of type II, and 47 (15.9%) were of type III short noses (Table 1). LLC repositioning and ear cartilage onlay grafting were performed in 228 patients. Alar cartilage repositioning and ear cartilage extension grafting with or without ear cartilage onlay grafting were performed in 67 patients. Patients were followed up for a minimum of 6 months and a maximum of 5 years (mean, 3.8 y) at 1, 4, and 24 weeks and at 1, 2, 4, and 5 years postoperatively.

Postoperatively, the swelling began to subside at 2 weeks and improvements in short nose and retracted nostrils were noted. The elongated and enlarged nose made the face appear smaller and more proportioned (Figs. 7 and 8). The nasal tips were movable and softened as swelling subsided (See video, Supplemental Digital Content 1, <http://links.lww.com/PRSGO/A9>). Mobility and softness of the nasal tip were maintained postoperatively.

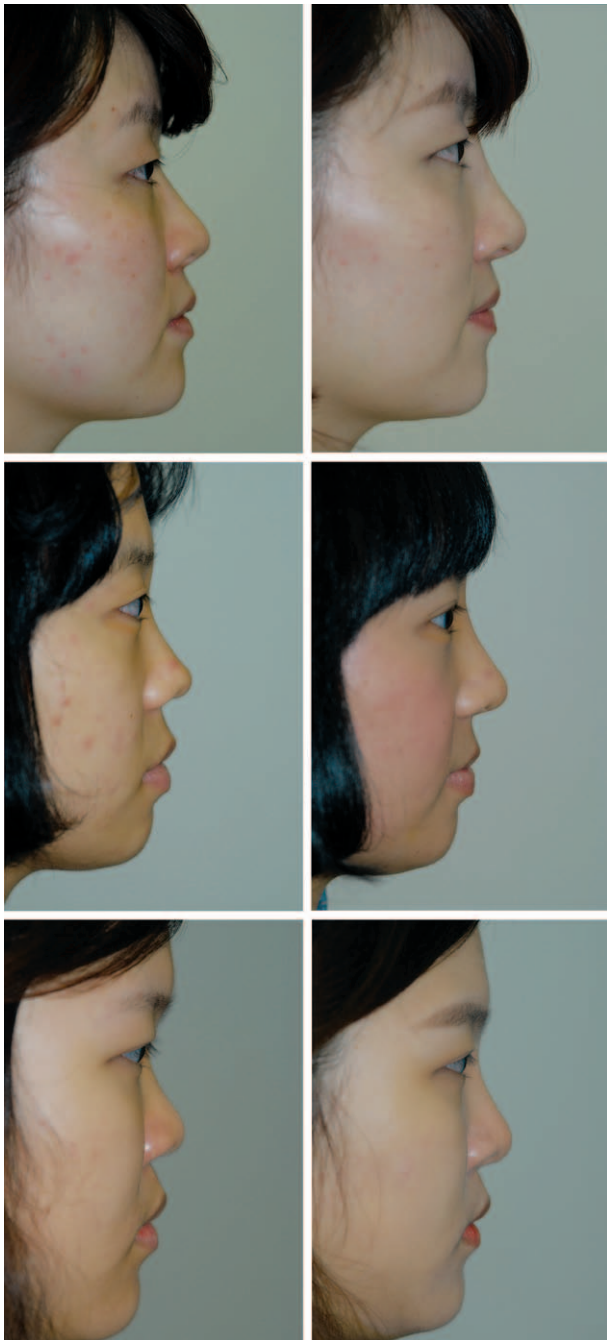
Seven patients had opened marginal incision sites or partial marginal wound necrosis. They were treated with wound debridement and re-closure with sutures (Table 3). One patient with type I short nose who had delayed follow-up experienced incision site wound opening and developed secondary infection. In this patient, all cartilage grafts and implants were removed, and the patient underwent revisional surgery with dermis grafting. Tip plasty and ear cartilage grafting were performed once the infection cleared. Among the 7 patients who experienced marginal incision site complications, 3 had



**Fig. 7.** Frontal view of patients before (A, C, and E) and after (B, D, and F) correction of short nose with lower lateral cartilage repositioning, ear cartilage grafting, Medpor columellar strut grafting, and dorsal silicone implantation. A and B, Marginal-type short nose. C and D, Basal-type short nose. E and F, Severe short nose.

type I short nose, 2 had type II short nose, and 2 had type III short nose. We believe that significant augmentation imposes excessive tension at the incision sites and strains healing of the skin edges of the wound.





**Fig. 8.** Lateral view of patients before (A, C, and E) and after (B, D, and F) correction of short nose with lower lateral cartilage repositioning, ear cartilage grafting, Medpor columellar strut grafting, and dorsal silicone implantation. A and B, Marginal-type short nose. C and D, Basal-type short nose. E and F, Severe short nose.

### DISCUSSION

Although the short nose condition has been defined by many surgeons in the past, a consensus has not been reached on the exact definition of short nose.<sup>1,2</sup> The authors characterized 3 conditions of short nose: short nasal tip, short alar rim (alar retraction), and



**Video Graphic 1.** Video demonstrating the tip mobility of the authors' technique. See video, Supplemental Digital Content 1, <http://links.lww.com/PRSGO/A9>.

**Table 3. Short Nose Correction Postoperative Complications (n = 295)\***

Complications	% (Cases)
No complications	97.6 (288)
Marginal incision site complications	
Type I	0.10 (3)
Type II	0.07 (2)
Type III	0.07 (2)

\*The case number consists of the total short nose cases performed.

short columellar base (columellar retraction). The authors diagnosed short nose when a patient exhibited 2 or more conditions simultaneously. Short nose was also classified based on different combinations of the conditions. Type I short nose was defined as a nose with a short nasal tip and alar retraction, type II short nose was defined as a nose with a short nasal tip and columellar retraction, and type III short nose was defined as a nose with a short nasal tip, alar retraction, and columellar retraction. Anatomically, the development and position of the lateral, intermediate, and medial crura were considered in the determination of the types of short noses. The LLC was positioned relatively caudally in type II short nose compared with types I and III. In types I and III short nose, the LLC was positioned relatively more cephalically (Fig. 2).

Technically, correction of short nose is a difficult procedure in Asian rhinoplasty for mainly 2 reasons. The first reason is that patients with short nose have weak and smaller amounts of cartilage. The other reason is that nasal skin in Asians tends to be thicker and less elastic compared with that of whites. Tight nasal skin can restrict nasal augmentation by producing greater opposing and compressive force.

Other techniques, such as those that use L-shaped silicone implants, dorsal silicone implants with auricular cartilage grafting, or complete autologous costal cartilages, have been performed. The use of

L-shaped silicone implants without cartilage grafting or nasal cartilage repositioning for nasal augmentation has been advocated by Flowers.<sup>6</sup> However, this implant shape has been associated with implant extrusion, and these L-shaped implants are not widely used in South Korea. Ahn et al<sup>7</sup> described a technique of placing only a dorsal silicone implant and using an auricular cartilage graft as a cap graft to elevate the nasal tip and to prevent silicone extrusion. However, this technique does not address columellar retraction, and neither of these techniques address alar retraction. Complete autologous rhinoplasty with costal cartilage in Asians was reported to have a complication rate of 16.8% by Park and Jin.<sup>8</sup> Specific complications were due to costal cartilage warping, infection, and chest hypertrophic scars. Cervelli et al<sup>9</sup> experience 9.1% reoperation rate with complete autologous rhinoplasty with costal cartilage due to graft dislocation, resorption, and aesthetic dissatisfaction.

To elongate the nasal tip, septal cartilage extension grafting or costal cartilage grafting has also been performed.<sup>2,8</sup> However, septal cartilage is often underdeveloped in patients with short nose and is insufficient in size for grafting. If sufficient septal cartilage is harvested or costal cartilage is used for septal extension grafting, or if the extended columellar strut is fixed to the maxilla, the resultant tip will be rigid. The rigidity of the tip hinders mobility of the nasal tip, resulting in a tip that feels stiff to the patient and to others making contact with the nose. Even with a strong tip support, persistent alar retraction will be seen if the entire alar cartilage is not addressed and lengthened (Fig. 1A). Persistent alar retraction in patients who had undergone prior augmentation rhinoplasty with rigid tip supports was corrected with alar cartilage repositioning, ear cartilage grafting, and floating Medpor strut grafting (Fig. 1B).

The LLC is mobile and it can be significantly altered during rhinoplasty. The LLC is connected superiorly to the upper lateral cartilage by fibrous connective tissue at the scroll and held laterally at the hinge region.<sup>10-12</sup> The undersurface of the LLC is connected to the vestibular skin. In short nose, adequate tip elongation is not possible when the LLC remains connected to the upper lateral cartilage (at the scroll), hinge region, or underlying vestibular skin. This can be tested by pulling the domal portion of the LLC toward the midline. Rather than elongating forward, the tip would rotate superiorly with limited elongation.<sup>13</sup> Therefore, we completely released all the retaining components of the LLC (at the scroll, hinge region, and underlying vestibular skin), except at the footplate. Freeing the lateral, intermediate, and medial crura (while preserving the connection at the footplate) allowed the alar carti-

lage to be mobile while maintaining its base. The position of the tip was further stabilized by the Medpor floating strut and the dorsal silicone implant. The Medpor floating strut provided enough tip support to counteract the recoil compressive force of the nasal skin envelope. Thus, it prevented drooping of the nasal tip, a common complication of short nose correction, postoperatively. In addition, the floating component of the strut graft allowed the tip to be pushed down when external force was applied. The dorsal silicone implant was connected to the tip cephalically and prevented the tip from overrotating.

By completely repositioning the LLC, the caudal margins of the lateral crura were rotated so that they were at the same level with the cephalic margins of the lateral crura. This alignment added support and definition to the alar lobule and alar margins and resulted in more favorable contouring of the nasal tip.<sup>5</sup> The realigned lateral crura were further enhanced by transversely positioned ear cartilage grafts. These horizontal grafts further supported the tip margins and alar margins. In our technique, the LLC was held up by the dorsal implant cephalically, the Medpor strut caudally, and reinforced anteriorly with ear cartilage grafts. Because the LLC was tented up and prevented from buckling by the reinforced buttresses mentioned above, alar collapse or internal valve insufficiency was not observed in our study.

In type II short nose, the medial and middle crura were cephalically positioned. In type III short nose, the entire lower LLC was cephalically positioned. Therefore, in significant type II or III short nose, alar cartilage repositioning alone was not sufficient for adequate lengthening. An extension graft was also used to push out the medial and middle crura caudally. We used symba cartilage cut longitudinally in half as an extension graft. A flexible ear cartilage extension graft with limited force was used to correct retracted columella because the LLC was freed from retaining forces. The advantage of using a flexible ear cartilage extension graft (instead of a firmer septal or costal cartilage graft) and a floating Medpor strut graft was the allowance of tip mobility. In type III short nose, additional onlay grafts were necessary to further project the lower third of the nose.

However, in very severe cases of type III short nose where the caudal end of the septal cartilage is severely retracted or underdeveloped (such as in Binder syndrome), columellar extension grafting with a conchal graft would be difficult because the flexible graft would not transfer enough force to achieve effective tip and columellar extension. In these very severe cases, a firmer costal cartilage graft would be needed.

Excessive augmentation imposes tension at the incision sites and strains survival of the skin flap. This

can lead to slight marginal necrosis and incision site opening. This complication can be prevented by taking caution when detaching the alar cartilage from the vestibular skin, and not excessively elongating the tip. We did not experience any tip necrosis or graft extrusion. The floating strut allowed the nasal tip to descend when there was significant tension at the tip due to compression from the skin envelope. This mechanism that allowed the mobile tip to descend prevented excess pressure from mounting on the skin of the nasal tip, and possibly, tip necrosis or graft extrusion.

### CONCLUSIONS

In our study, we have found LLC repositioning and ear cartilage grafting techniques to be effective in correcting short nose in Asians, with a low incidence of complications. Advantages of this technique include elongation of the entire nasal tip and ala, which results in more comprehensive and proportioned nasal augmentation. The mobile nasal tip is maintained by adequately freeing the retaining forces of the LLC while providing enough structural support.

*Jin Suk Byun, MD, PhD*  
Dong Sung Plaza, 3rd Floor  
59 Sail-dong, Jung-gu, Daegu  
Kyung-sang-do, South Korea  
E-mail: byunjs55@hanmail.net

### REFERENCES

1. Matsunaga RS. Augmentation rhinoplasty of Asian noses. *Facial Plast Surg Clin North Am.* 1996;4:75–85.
2. Park JH, Jin HR. Use of autologous costal cartilage in Asian rhinoplasty. *Plast Reconstr Surg.* 2012;130:1338–1348.
3. Byrd HS, Andochick S, Copit S, et al. Septal extension grafts: a method of controlling tip projection shape. *Plast Reconstr Surg.* 1997;100:999–1010.
4. Toriumi DM, Patel AB, DeRosa J. Correcting the short nose in revision rhinoplasty. *Facial Plast Surg Clin North Am.* 2006;14:343–355, vi.
5. Toriumi DM. New concepts in nasal tip contouring. *Arch Facial Plast Surg.* 2006;8:156–185.
6. Flowers RS. Nasal augmentation by the intraoral route. *Plast Reconstr Surg.* 1974;54:570–578.
7. Ahn J, Honrado C, Horn C. Combined silicone and cartilage implants: augmentation rhinoplasty in Asian patients. *Arch Facial Plast Surg.* 2004;6:120–123.
8. Park JH, Jin HR. Use of autologous costal cartilage in Asian rhinoplasty. *Plast Reconstr Surg.* 2012;130:1338–1348.
9. Cervelli V, Bottini DJ, Gentile P, et al. Reconstruction of the nasal dorsum with autologous rib cartilage. *Ann Plast Surg.* 2006;56:256–262.
10. Lam SM, Williams EF III. Anatomic considerations in aesthetic rhinoplasty. *Facial Plast Surg.* 2002;18:209–214.
11. Gruber RP, Kryger G, Chang D. The intercartilaginous graft for actual and potential alar retraction. *Plast Reconstr Surg.* 2008;121:288e–296e.
12. Rohrich RJ, Hoxworth RE, Thornton JF, et al. The pyriform ligament. *Plast Reconstr Surg.* 2008;121:277–281.
13. Anderson JR. The dynamics of rhinoplasty. In: *Proceedings of the 9th International Congress of Otorhinolaryngology.* Excerpta Medica, 1969.