

OPEN

# Correction of Severely Contracted Nose

Young Hwan Oh, M.D., Ph.D.

Je Won Seo, M.D.

Se Joon Oh, B.A.

Ick Tae Oum, M.D.

Gukjin Kim, M.D.

Jun Kim, M.D.

Sa Yong Kim, M.D.

Seung Woo Shin, M.D.

DaEun Park, B.S.

Kenneth K. Kim, M.D.

Seoul, Republic of Korea; and  
Los Angeles, Calif.



**Background:** Severely contracted nose is manifested with a tight and hardened nasal envelope. Expansion of the contracted skin is an important first step in correcting these revision cases. The underlying weak lower lateral cartilage makes the tip projection structurally difficult to achieve and maintain without rigid supporting cartilage grafting.

**Methods:** A total 59 of patients were treated with isolated adipose-derived stromal cells before revision surgery to soften the nasal envelope. Adipose tissues were digested at 37°C with sterile 0.075% collagenase type 2. The average isolated adipose-derived stromal cell count of each serial injection was  $5 \times 10^6$  cells (total injection volume, 0.5 ml;  $1 \times 10^7$  cells/ml). Intraoperatively, the lower lateral cartilage was released from surrounding scar tissue to allow for advancement. Rib cartilage and other autologous grafts were used in reconstruction of the internal framework.

**Results:** The follow-up period ranged from January of 2009 to April of 2014. The mean follow-up period was 10 months. Fifty-one of 59 patients were satisfied with their results. Eight patients underwent revision surgery for the following: infection (two patients), deviation (one patient), warping (two patients), and cosmetic dissatisfaction (three patients). There were two cases of additional warping, but the patients refused revision surgery. Nine patients required additional adipose-derived stromal cell injections at the tip.

**Conclusions:** The combination of isolated fat grafting to soften the nasal skin envelope and rigid tip support results in correction of silicone-induced contracted nose. There were no incidences of recurrent nasal contraction or ischemic injury. (*Plast. Reconstr. Surg.* 138: 571, 2016.)

**CLINICAL QUESTION/LEVEL OF EVIDENCE:** Therapeutic, IV.

The number of Asian rhinoplasty procedures using silicone implants has been increasing over time. With this rise in the number of cases, the number of complications has also risen. The most difficult problem to correct is a severely contracted nose. These patients present with a history of nasal infection and subsequent removal of the nasal implant. During the inflammatory and subsequent contracture stage, a significant amount of the nasal soft-tissue envelope transforms into scar tissue. The scar tissue is present not only in the subcutaneous layer, but also in the dermal layer. Excision of this scar tissue leads to extreme thinning

of the nasal envelope that can compromise blood supply to the overlying skin. Wide dissection and release of the capsule can correct mild to moderate nasal capsular contraction but does not adequately expand the nasal envelope in cases of severe contracture for tension-free redraping during revision surgery. In the severely contracted nose, the underlying nasal cartilage framework is also compressed or distorted, and the overall effect is a characteristically shortened nose.

There is no consensus on when to operate on patients with a contracted nose. The first step is to

From Oh and Young Plastic Surgery; and the Division of Plastic and Reconstructive Surgery, David Geffen School of Medicine at the University of California, Los Angeles.

Received for publication August 21, 2015; accepted April 27, 2016.

Copyright © 2016 by the American Society of Plastic Surgeons

This is an open-access article distributed under the terms of the Creative Commons Attribution-Non Commercial-No Derivatives License 4.0 (CCBY-NC-ND), where it is permissible to download and share the work provided it is properly cited. The work cannot be changed in any way or used commercially.

DOI: 10.1097/PRS.0000000000002516

**Disclosure:** The authors have no financial interest to declare in relation to the content of this article. No outside funding was received.

Supplemental digital content is available for this article. Direct URL citations appear in the text; simply type the URL address into any Web browser to access this content. Clickable links to the material are provided in the HTML text of this article on the *Journal's* Web site ([www.PRSJournal.com](http://www.PRSJournal.com)).

remove any foreign body to minimize any inflammation-inducing effects. If surgery is delayed for 6 months to 1 year, scar remodeling and maturation can occur. However, it is also possible that further contracture can occur with progression of the inflammatory process. When there was no sign of infection, we initiated adipose-derived stromal cell treatment to soften the existing scar tissue on the premise that prevention of further skin contracture is important for achieving optimal aesthetic results, as reexpansion of the severely contracted nose is difficult to achieve.<sup>1-5</sup>

Prior reports have suggested the use of fat grafting to soften the effect of scar tissues.<sup>6-8</sup> We isolated adipose-derived stromal cells from harvested fat grafts to increase the regenerative effect, and serially injected them into the nasal scar tissue before revision surgery. Underlying support with rib cartilage and other autologous grafts were used to reconstruct the internal framework.

## PATIENTS AND METHODS

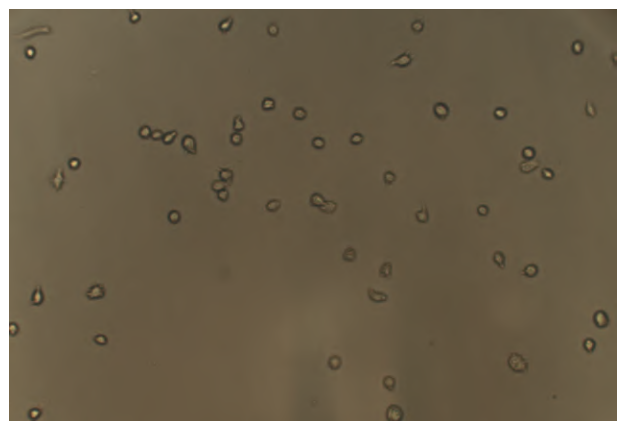
From September of 2006 to January of 2014, a total of 80 patients were included in a study to correct a severely contracted nose. Fifty-nine patients underwent presurgical treatment with adipose-derived stromal cell injection and revision rhinoplasty. Twenty-one patients were in the control study where they underwent presurgical treatment with saline injections and revision rhinoplasty. The age of patients ranged from 17 to 63 years. Nine patients (11.25 percent) were male and 71 were female (88.75 percent). The patients in this study had an average of 3.21 prior rhinoplasty procedures. Patients were selected in accordance with the following inclusion criteria: severe contracted and shortened nose, nasal tip skin depression or dimpling, and firm and immobile nasal envelope. Forty-five patients (57.0 percent) underwent early (within 6 months from prior revision surgery) revision rhinoplasty. Fourteen patients (17.7 percent) underwent revision rhinoplasty within 6 months to 1 year. Twenty-four patients (30.4 percent) underwent revision surgery after 1 year from their prior revision rhinoplasty.

### Presurgical Treatment

Adipose-derived stromal cell injections were given as soon as the patients presented to our clinic. None of the patients exhibited active signs of infection, such as pus drainage, fluctuance, tenderness, or significant erythema. Photographs were taken before and after each treatment, and mobility of the nasal envelope was documented.

The adipose tissues were harvested from patients by injection of tumescent fluid followed by fat harvesting from the abdomen or thigh with hand-held liposuction cannulae. The average amount of harvested fat tissue was 43.3 ml. The harvested adipose tissue was centrifuged for 3 minutes at 3000 rpm. Collected adipose tissues were processed in a Good Manufacturing Practice facility authorized by the Ministry of Food & Drug Safety. Adipose tissues were digested at 37°C with sterile 0.075% collagenase type II (Worthington Biochemical Corp., Lakewood, N.J.), liquefied by normal saline solution, then incubated for 40 minutes. After digestion, stromal vascular fraction was separated from the tissue solution by centrifugation at 400 *g* for 5 minutes, and washed with gentamicin-containing Hartmann solution three times. Adipose-derived stromal cells were filtered through a 100- $\mu$ m cell strainer (BD Biosciences, San Jose, Calif.) to remove undigested connective tissue, blood vessels, and other debris (Fig. 1). The cell numbers were counted, and adipose-derived stromal cells ( $1 \times 10^7$  cells/ml) were aliquoted to cryovials for single injection in 10% dimethyl sulfoxide (Sigma-Aldrich, St. Louis, Mo.) solution. These cryovials were stored in liquid nitrogen for future serial use (Fig. 2).

The average count of adipose-derived stromal cells of each injection was  $5 \times 10^6$  cells (total injection volume, 0.5 ml;  $1 \times 10^7$  cells/ml). Injection areas included the nasal tip and any region with significant scar tissue. The depth of the injection was at the subcutaneous layer, and performed aseptically. Injection was started, provided that the patient did not demonstrate any signs of infection, such as erythema or pus. The average time between injections was 2 days. The average treatment duration (softening effect) was 28.7 days with an average



**Fig. 1.** Isolated adipose-derived stromal cells (original magnification,  $\times 10$ ).




**Fig. 2.** Adipose-derived stromal cells in vials, stored in nitrogen chamber.

of 11.5 injections (minimum, seven; maximum, 27). The number of injections was determined based on clinical observation of tissue response to adipose-derived stromal cells (whether the nasal envelope softened and would expand to nasal augmentation as planned). There were no significant delays between injection and surgery.

Before revision rhinoplasty, confirmation of softening of the nasal skin envelope was documented and videotaped. Expansion of the nasal envelope was considered adequate when the nasal dorsal skin and nasal tip showed sufficient movement with gentle digital manipulation. [See Video, Supplemental Digital Content 1, which shows preoperative nose movement of a




**Video 1.** Supplemental Digital Content 1 shows preoperative nose movement of a 29-year-old patient (case 1) exhibiting nasal skin immobility, skin discoloration, multiple dimpling, and cobblestone-like nasal envelope, <http://links.lww.com/PRS/B787>.

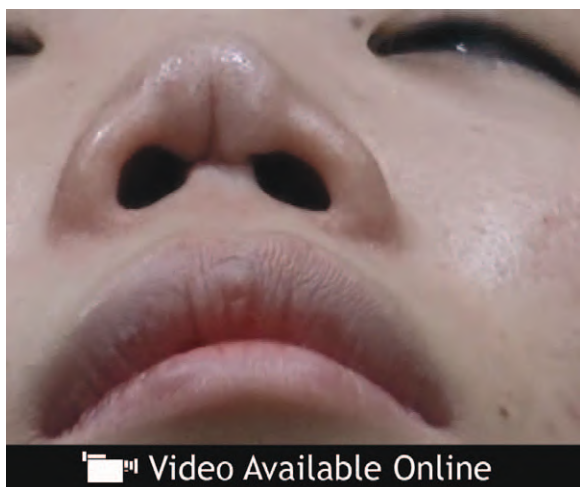


**Video 2.** Supplemental Digital Content 2 shows the patient in case 1 after 2 months (24 injections) of adipose-derived stromal cell therapy. Improvement in nasal skin mobility, skin discoloration, and skin dimpling can be observed, <http://links.lww.com/PRS/B788>.

29-year-old patient (case 1) exhibiting nasal skin immobility, skin discoloration, multiple dimpling, and cobblestone-like nasal envelope, <http://links.lww.com/PRS/B787>. See Video, Supplemental Digital Content 2, which shows the patient in case 1 after 2 months (24 injections) of adipose-derived stromal cell therapy. Improvement in nasal skin mobility, skin discoloration, and skin dimpling can be observed, <http://links.lww.com/PRS/B788>. See Video, Supplemental Digital Content 3, which shows preoperative nose movement of a 25-year-old woman (case 2) exhibiting tight immobile nasal skin and severely retracted columella, [http://](http://links.lww.com/PRS/B789)




**Video 3.** Supplemental Digital Content 3 shows preoperative nose movement of a 25-year-old woman (case 2) exhibiting tight immobile nasal skin and severely retracted columella, <http://links.lww.com/PRS/B789>.




**Video 4.** Supplemental Digital Content 4 shows the patient in case 2 after 40 days (26 injections) of adipose-derived stromal cell therapy to soften the nasal envelope. Improvement in nasal skin mobility can be observed, <http://links.lww.com/PRS/B790>.

[links.lww.com/PRS/B789](http://links.lww.com/PRS/B789). See Video, Supplemental Digital Content 4, which shows the patient in case 2 after 40 days (26 injections) of adipose-derived stromal cell therapy to soften the nasal envelope. Improvement in nasal skin mobility can be observed, <http://links.lww.com/PRS/B790>.]

The control group received saline injection for 1 month with an average of 14.1 injections. The saline injection area included the nasal tip and any region with significant scar tissue. The depth of the injection was at the subcutaneous layer. The limit of each saline injection session was noted when blanching of the skin occurred on the nose. The amount of nasal envelope expansion and tip movement was documented before and after saline injections. (See Video, Supplemental Digital Content 5, which shows preoperative nose movement in a control case, <http://links.lww.com/PRS/B791>.)



**Video 5.** Supplemental Digital Content 5 shows preoperative nose movement in a control case, <http://links.lww.com/PRS/B791>.



**Video 6.** Supplemental Digital Content 6 shows 3-month postoperative nose movement in a control case. There is no significant improvement in expansion of the nasal envelope, <http://links.lww.com/PRS/B792>.

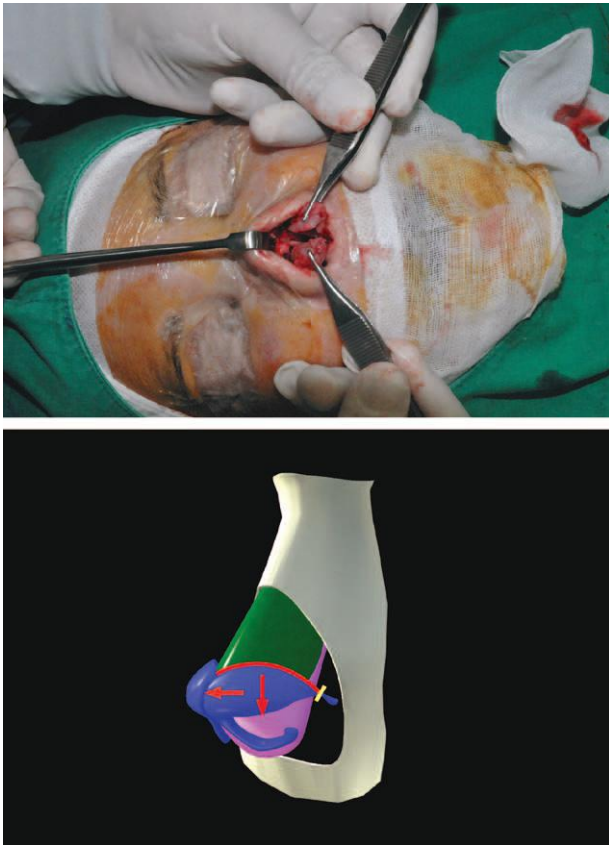*PRS/B791.* See Video, Supplemental Digital Content 6, which shows 3-month postoperative nose movement in a control case. There is no significant improvement in expansion of the nasal envelope, <http://links.lww.com/PRS/B792>.)

### Operative Method

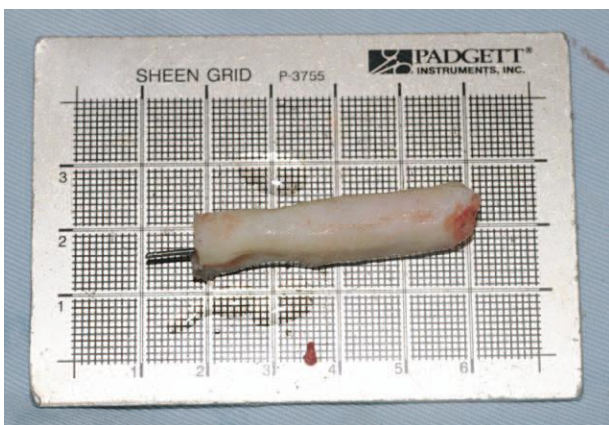
Revision surgery was performed as soon as the nasal envelope softened adequately and could be moved with gentle digital manipulation. For the control group, revision rhinoplasty was performed 1 month after saline injections. Prior open rhinoplasty incision was used to separate the nasal envelope from the lower and upper lateral cartilages and bone. Wide dissection was performed in the plane below the softened capsule. Lower lateral cartilages were released at the scroll, hinge, and membranous septum to allow mobility of the lower lateral cartilages in cephalad and caudal directions.<sup>9</sup> Adequate release was confirmed by mobility at the desired tip position without tension (Fig. 3).

In our study, all patients exhibited inadequate tip projection and insufficient septal cartilage to serve as a donor site for septal extension because of multiple operations and severe inflammation.<sup>2,4,5</sup> Therefore, a rib cartilage graft was harvested from the eighth or ninth rib to serve as a columellar strut graft.

The harvested eighth or ninth rib cartilage was cut in half and sculpted to the proper size based on the desired tip projection. The outer cortex was removed, and a symmetrical carving technique was performed to minimize warping (Fig. 4). The base of the two rib cartilage grafts was fixed to the anterior nasal spine and/or septal base with 5-0 polydioxanone sutures (Fig. 5). The position



**Fig. 3.** (Above) Intraoperative photograph of downward rotation of alar cartilage. (Below) Schematic diagram of downward rotation of alar cartilage. The lower lateral cartilage was freed at the scroll, hinge, and the membranous septum to allow for caudal and upward mobilization. (White) Nasal bone; (green) upper lateral cartilage; (blue) lower lateral cartilage; (pink) septal cartilage; (red line) scroll area; (yellow line) hinge; (red arrow) caudal rotation and tip projection of lower lateral cartilage.



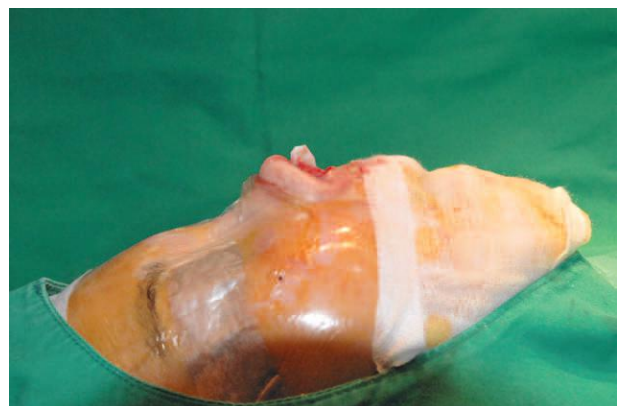**Fig. 4.** The outer cortex was removed and warping was minimized by symmetrical carving technique.

and the angle of the rib cartilage graft fixation were adjusted according to the desired nasolabial angle. Caudal and upward mobilization of the lower lateral cartilages was performed, and they were sutured to the columellar strut graft using 5-0 polydioxanone sutures. In cases of alar asymmetry or alar retraction, additional ear cartilage or an auricular composite graft was used.<sup>10</sup> Moderate to severe dorsal augmentation was achieved with carved rib cartilage,<sup>11</sup> and minimal dorsal augmentation was achieved with dermal fat grafting.<sup>12,13</sup>

## RESULTS

The follow-up period ranged from 1 to 7 years (mean, 2.3 years). The patients were evaluated by the operating surgeon and three other surgeons. Resolution was defined as short nose correction to the satisfaction of both the surgeons and the patients. Presurgical treatment with adipose-derived stromal cells showed improvement of nasal envelope contracture and improvement of nasal tip dimpling and contracture (Tables 1 and 2). We did not notice loss of efficacy over time. The improvement in tip dimpling without any complications was defined by conversion of concavity of the tip skin to convexity. We did not see any significant further scar contractures. However, we did see minor scar contracture that would typically be expected with any rhinoplasty procedure. At 6 months postoperatively, the outcomes remained stable and consistent.

In the group treated with adipose-derived stromal cells preoperatively, eight patients (13.5 percent) underwent revision rhinoplasty after the operation. The reasons for revision surgery were infection (two patients), deviation (one patient), warping (two patients), and cosmetic dissatisfaction (three patients). The nasal infections were treated with antibiotics, including



**Fig. 5.** Intraoperative photograph of septal extension using rib cartilage.

**Table 1. Improvement of Nasal Envelope Contracture and Resolution of Nasal Tip Dimpling and Contracture**

Tip Dimpling and Contracture Resolution Observed	No. of Cases (%)
No improvement	0 (0)
Resolution of tip before surgery	50 (84.7)
Resolution of tip after surgery and additional isolated ADSC injection	9 (15.3)

ADSC, adipose-derived stromal cell.

**Table 2. Methods of Dorsal Augmentation**

Dorsal Augmentation	No. of Cases (%)
Carved en bloc rib cartilage	38 (67.9)
Dermal fat graft	18 (32.1)

**Table 3. Postoperative Results**

Postoperative Results	No. of Cases (%)
No complications	51 (86)
Infection	2 (3.3)
Deviation	1 (1.6)
Warping	2 (3.3)
Cosmetic dissatisfaction	3 (5)
Total complications	8 (13.5)

intraoperative antibiotics, irrigation, and postoperative antibiotic administration for 2 weeks. Patients with cosmetic dissatisfaction underwent revision surgery 6 months later without further complications. Two patients with warping refused to undergo further surgical correction. There were no other postoperative complications (Table 3).

In cases of severely deformed nasal tip or delayed wound healing at the nasal tip after surgery, additional adipose-derived stromal cell injections were applied. Nine patients (15.2 percent) received additional isolated adipose-derived stromal cell therapies 2 days after the operation (Figs. 6 and 7). They received on average 9.2 injections during a period of 15 days. Patients who received postoperative adipose-derived stromal cell injections had improvement in tip dimpling without any complications.

## CASE REPORTS

### Case 1

A 29-year-old patient exhibited skin discoloration, hardness, significant dimpling, and a cobblestone-like nasal envelope. Her surgical history included six prior rhinoplasties. She had her first surgery 10 years previously. During prior operations, silicone and Gore-Tex (W. L. Gore & Associates, Flagstaff, Ariz.) implants were used. Donor sites for prior grafts included septum, bilateral ear, and seventh rib cartilage. Six months before our treatment, she received Juvéderm (Allergan, Inc., Irvine, Calif.) filler

injection from another clinic after nasal implants, and grafts were removed because of infection.

She received adipose-derived stromal cell therapy for 2 months (24 times) and showed improvement in skin discoloration and skin dimpling. After confirming the mobility of the nasal skin envelope, she underwent revision rhinoplasty. The rhinoplasty was performed using autologous ninth rib cartilage and dermal fat grafts. A composite scapha graft was also used to correct alar retraction. After rhinoplasty, she underwent additional adipose-derived stromal cell injections on the nasal tip for 2 weeks (Fig. 6).

### Case 2

A 25-year-old woman presented with tight immobile nasal skin and severely retracted columella. Her surgical history included five rhinoplasties. The first operation was performed 5 years previously. Two months previously, her silicone implant and cartilage grafts were removed because of infection. The patient underwent 40 days of isolated adipose-derived stromal cell treatment (26 times) to soften the nasal envelope. The patient then underwent revision rhinoplasty with autologous ninth rib cartilage for columellar strut grafting and dermal fat grafting for dorsal augmentation. The defect region at the soft triangle was treated with auricular composite grafting<sup>14</sup> (Fig. 7).

### Case 3

A 22-year-old patient presented with a history of three rhinoplasties. The last operation was performed 2 months previously with a silicone implant and irradiated homologous costal cartilage. She then developed nasal infection, and 2 weeks before visiting our clinic, the implant and graft were removed. Severe infection and sustained inflammation collapsed the nostril and led to columella retraction. After 18 adipose-derived stromal cell treatments during a period of 30 days, the nasal envelope became soft and mobile. The autologous rib cartilage grafts from the seventh and ninth ribs were used for dorsal augmentation and columellar strut grafting, respectively. The patient was dissatisfied with the incomplete correction of the columellar retraction. Six months later, the retracted columella was further corrected with auricular grafting (Fig. 8).

The control group did not show any improvement in expansion of the nasal envelope or improvement of the nasal tip dimpling or mobility. One month after saline injections, all 21 patients underwent revision rhinoplasty with rib cartilage grafts. There was one case of nasal infection, which was treated with local antibiotic irrigations and oral antibiotics. One patient had warping of the dorsal bridge, which required revision surgery. Eight patients were dissatisfied with inadequate tip projection and overall aesthetic outcome (Fig. 9). None of these eight patients wished to undergo further corrective surgery.

## DISCUSSION

There are two factors that need to be addressed in the correction of the severely contracted nose. One is expansion of the constricted nasal envelope, and the other is reestablishment of the desired stable internal framework. Expansion of the soft tissue in the contracted nose needs

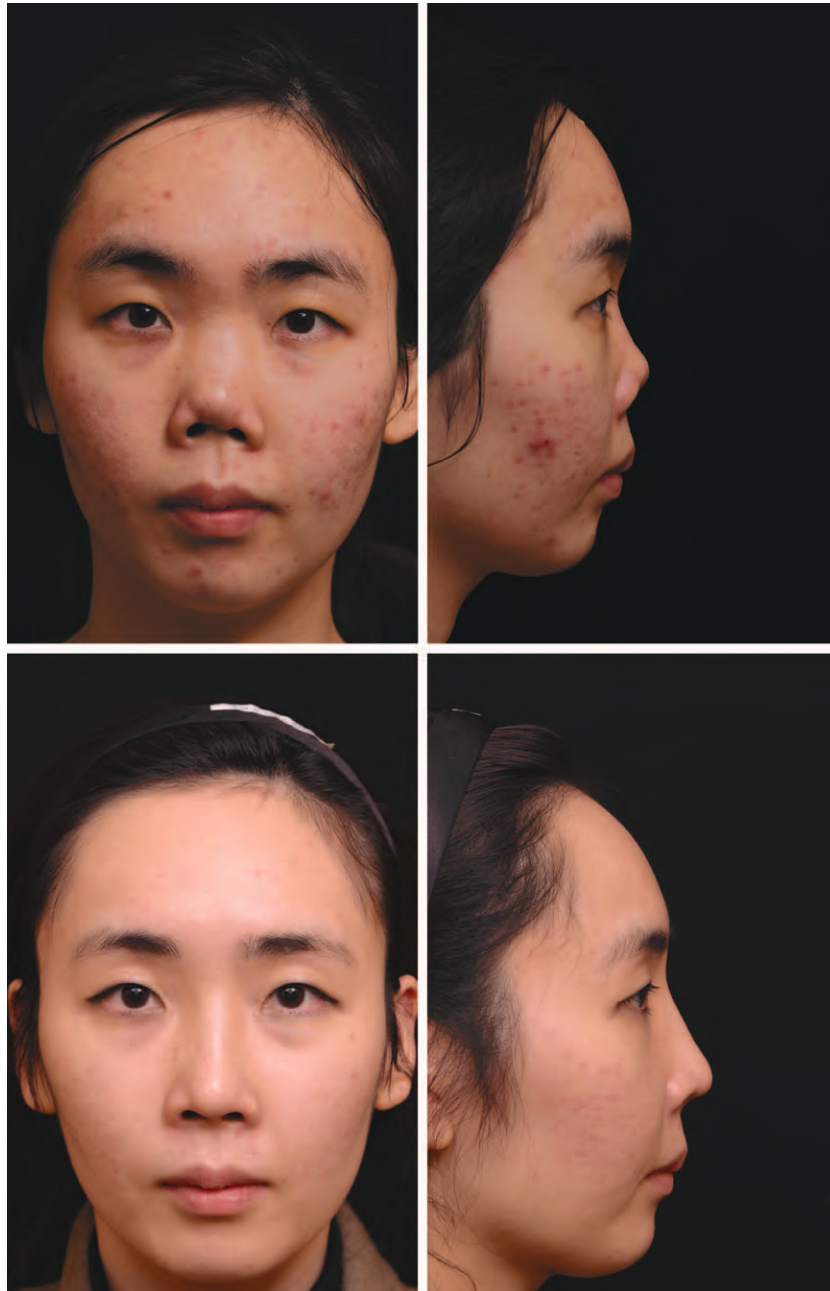

**Fig. 6.** Case 1. (Above, left) Preoperative image (anterior view). (Above, center) Preoperative image (lateral view). (Above, right) After adipose-derived stromal cell therapies, the skin discoloration and multiple skin dimpling showed improvement. (Below, left) Satisfactory results 10 months after rhinoplasty (anterior view). (Below, right) Satisfactory results 10 months after rhinoplasty (lateral view).

to be sufficient to allow for tension-free redraping during revision augmentation.

There are two ways to expand the nasal skin envelope. One is intraoperative expansion by means of wide dissection; the other is by softening the nasal envelope before surgery. First, in the mild or moderately contracted nose, intraoperative expansion by means of wide dissection of the nasal envelope from the surrounding cartilages, bone, and retaining ligaments is often sufficient to allow for tension-free redraping. However, in the severely contracted

nose, the tight constricted nasal envelope does not expand adequately even with wide dissection. The limiting factor is the intrinsic thickening of the entire nasal envelope, including the skin. Even if the nasal envelope is maximally expanded intraoperatively, the tight nasal skin exerts pressure on the reconstructed internal framework, especially at the tip. Second, the vascular supply to the nasal envelope is tenuous from multiple surgical traumas and inflammation. Aggressive wide undermining may compromise the blood supply to the nose.



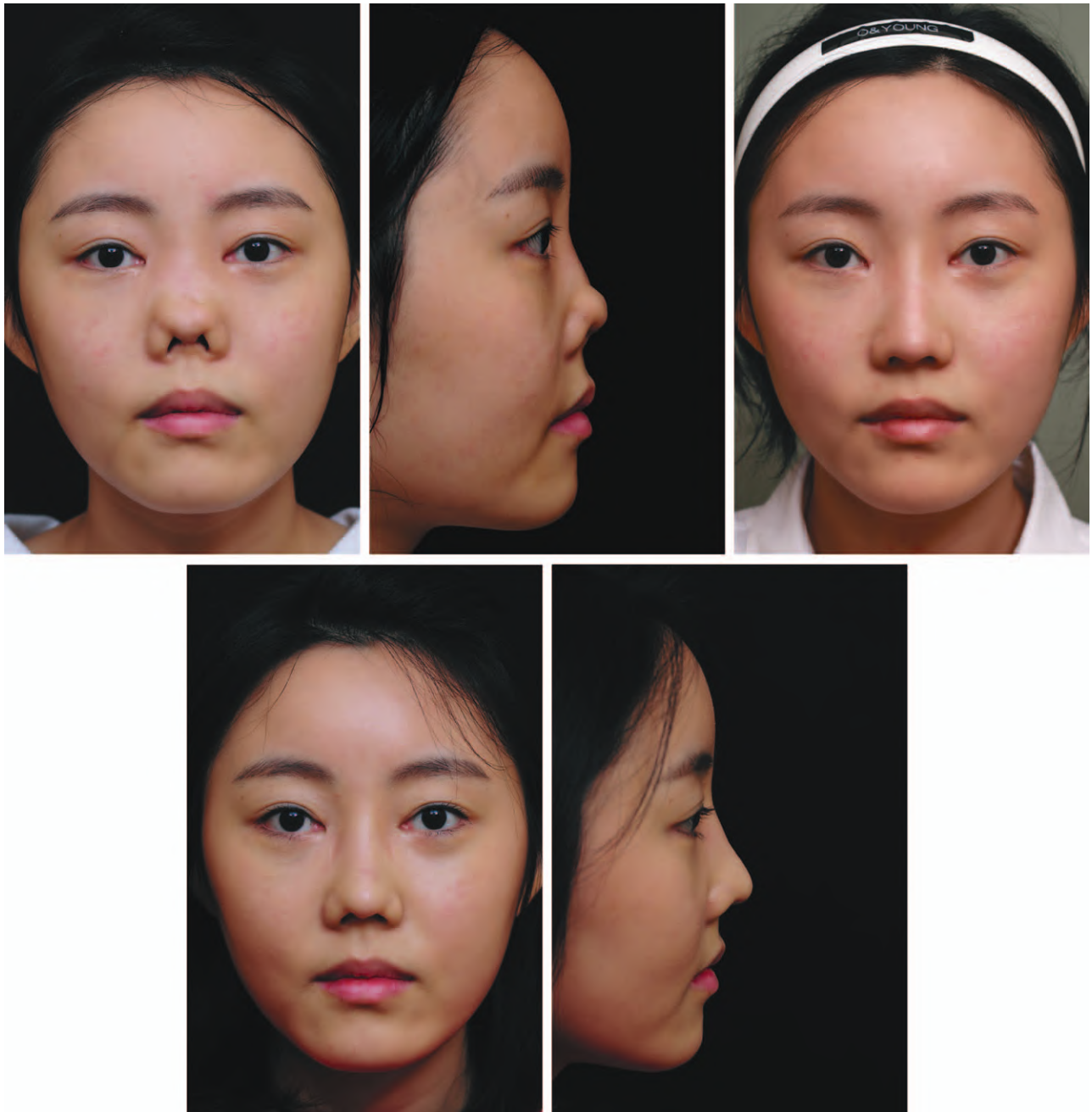**Fig. 7.** Case 2. (Above, left) Preoperative image (anterior view). (Above, right) Preoperative image (lateral view). (Below, left) Postoperative results 3 months after rhinoplasty (anterior view). (Below, right) Postoperative results 3 months after rhinoplasty (lateral view). Severely retracted columellar area was improved after rhinoplasty and adipose-derived stromal cell injections.

Our control group, which had saline injection to simulate the mass effect of tissue expansion before surgery, had insufficient skin envelope expansion. This is because patients with a severely contracted nose have hard scar tissue not only in the subcutaneous layer but also in the dermis. The mass effect of tissue expansion cannot restore the fibrotic dermis into healthy pliable dermis. We

have also tried nonprocessed fat grafts in the past without any significant benefit.

We believe that the effectiveness of adipose-derived stromal cells is attributable to a high level of mesenchymal stem cells, which have regenerative properties.<sup>15-17</sup> These properties have been noted in various clinical settings, including treatment of acute complications of nasal skin necrosis



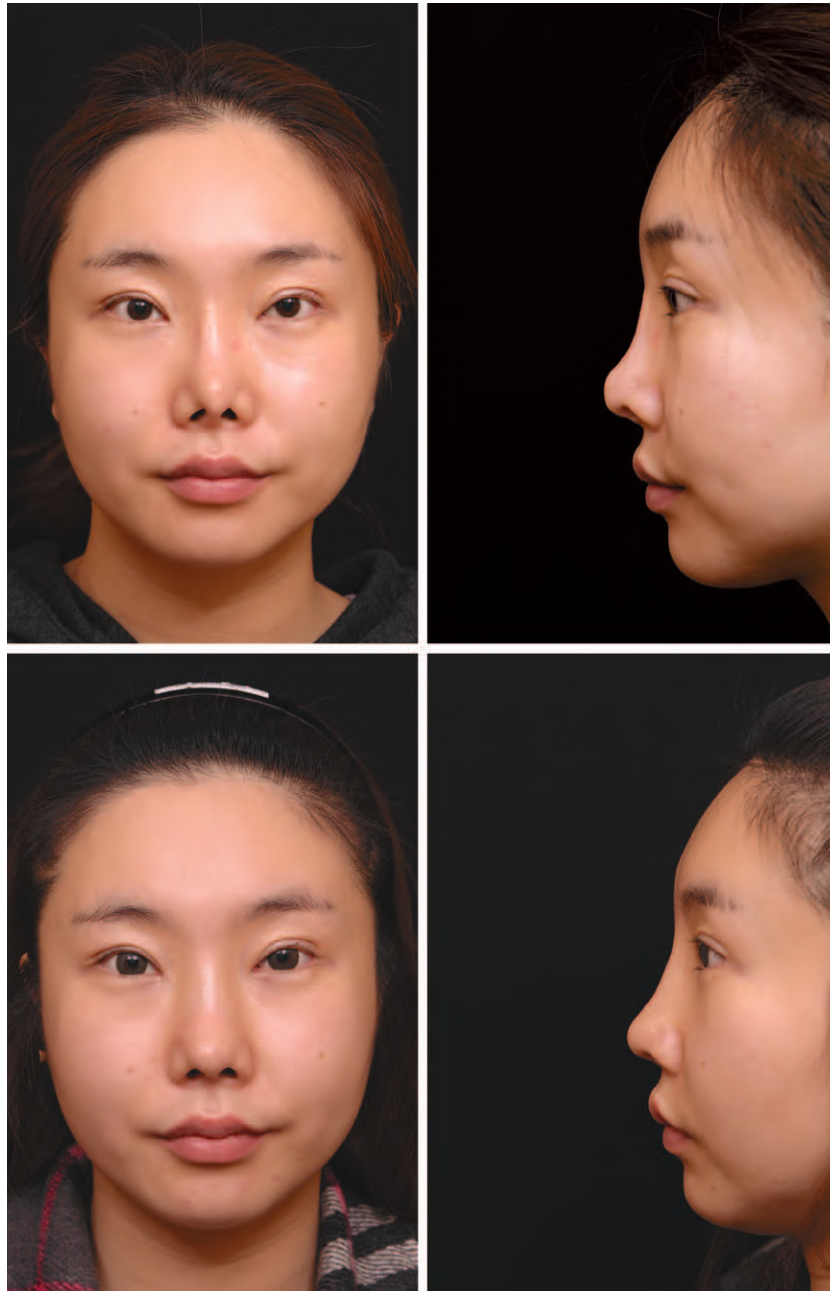

**Fig. 8.** Case 3. (Above, left) Preoperative image (anterior view). (Above, center) Preoperative image (lateral view). (Above, right) Improvement in the nasal alar and lobule after 6 months. Inadequate correction of the columella can be seen. (Below, left) Improvement in columella retraction with auricular composite grafting after 1 year (anterior view). (Below, right) Improvement in columella retraction with auricular composite grafting after 1 year (lateral view).

after filler injection.<sup>18</sup> Adipose-derived stromal cells increased angiogenesis, which was visualized and assessed by CD31 and NG2 immunofluorescence stains and thermal infrared imaging.<sup>19–21</sup> Therefore, adipose-derived stromal cells can be a therapeutic modality for ischemic conditions.<sup>22</sup> In addition, adipose-derived stromal cell injection increased collagen synthesis and the number of

fibroblasts in a mouse model.<sup>21</sup> In chronic non-healing wounds, such as Crohn fistulae, adipose-derived stromal cell treatment led to wound closure.<sup>23</sup>

We isolated adipose-derived stromal cells from harvested fat grafts through an enzymatic digestion and filtration process. By concentrating isolated adipose-derived stromal cells, we increased



**Fig. 9.** Control case. (Above, left) Preoperative image (anterior view). (Above, right) Preoperative image (lateral view). (Below, left) Three-month postoperative image (anterior view). (Below, right) Three-month postoperative image (lateral view).

the number of adipose-derived stromal cells per amount injected. It is possible that growth factors were depleted during the process of adipose-derived stromal cell isolation. Although we did not directly compare fat grafting itself to adipose-derived stromal cell therapy, we found that adipose-derived stromal cell isolation effectively softened the hardened and contracted nasal envelope. Our method does not require cell culturing and is relatively simple to perform for use in a clinical setting.

By converting the hardened and contracted nasal envelope to a soft, mobile nasal envelope, we did not need to excise capsule or perform an extensively wide dissection. Excision of the capsule can lead to nasal envelope irregularity or excessive thinning of the nasal skin. Because these patients underwent multiple operations, the blood supply to the nasal skin was already tenuous. Avoiding extensive dissection and excision of the capsule minimizes circulation injury.

Although all our patients presented to our clinic after the implant was removed, certainly adipose-derived stromal cells can be injected at the time of implant removal in the absence of infection.

In reestablishing the internal framework, tip projection, dorsal augmentation, and alar composite grafting were needed. For the tip projection, ninth rib cartilages were used in all our series as a columellar strut. Patients in our study already had septal and ear cartilage grafts. The rigid columellar strut served as a stable platform for the lower lateral cartilage to attach and remain at its desired position during the healing process. In addition, the extended tip position also tents the expanded dorsal skin and therefore helps maintain adequate space for the dorsal grafts. The dorsal graft is a carved rib cartilage graft or dermal fat graft depending on the dorsal height desired. A rib cartilage graft was used for moderate to significant dorsal projection, whereas a dermal fat graft was used for minimal augmentation. Although dermal fat grafts do not have firm or solid properties, the desired shape did not deform because of the minimal contractile force from the preexpanded soft nasal envelope. Other studies have used irradiated rib cartilages for internal framework,<sup>4,5</sup> but we found that irradiated cartilage exhibits unpredictable resorptive properties. The use of various autologous grafts should be determined based on the surgeon's preference or experience.

Nonsevere contracted ala can be solved with alar grafts.<sup>24</sup> However, in severely retracted ala, skin expansion with isolated fat injection was inadequate. Therefore, composite skin cartilage grafts from scapha were needed in our series.

Patients with the most severely pinched and depressed tips required additional postoperative adipose-derived stromal cell injections for the nasal tip skin to soften. Certainly, we could have delayed revision surgery until the nasal tip healed sufficiently. However, patients with these deformities experience significant psychological difficulty and wish to undergo surgery as soon as possible. These patients often avoid social gatherings, and their nasal deformities negatively affect them in their work settings as well. We believe that as long as the nasal skin was expanded sufficiently to allow the internal framework to be established without being buckled by the tight nasal envelope, surgery could proceed. Postoperative adipose-derived stromal cell injection facilitated tip depression healing and was a viable postoperative treatment.

The degree of capsule softening versus dermal softening was not quantified, nor did we quantify the movement after each injection. The injection

of adipose-derived stromal cells was in the plane between the capsule and the dermis. We did not see any fat grafts that we would normally see after fat grafting. We speculate that softening of both the capsule and the dermis contributed to softening of the overall softness of the nasal envelope. With each injection, there were improvements, but determining the amount of incremental improvement on the capsule and dermis would need further investigation on a standardized scar tissue model.

In our series, there were two cases of nasal infection. These two patients had significant postoperative swelling and seroma. The accumulated fluid was not drained and eventually led to infections that had to be treated with antibiotics for 1 month. Avoiding extensive wide dissection and meticulously applying external tape and compressive dressings to avoid dead space is important in avoiding seroma accumulation and potential postoperative infection.

## CONCLUSIONS

Preoperative injection of isolated adipose-derived stromal cells into the contracted nasal scar tissue resulted in softening of the nasal envelope. Intraoperative release of remaining scar tissue and reconstruction of the internal framework with autologous grafts resulted in stable postoperative results. There were no recurrences of contracture and there were no ischemic injuries to the overlying skin.

*Young Hwan Oh, Ph.D.*

Oh and Young Plastic Surgery Clinic  
574-3, Shinsa-Dong, Kangnam-gu  
Seoul, Republic of Korea

## PATIENT CONSENT

*Patients provided written consent for the use of their images.*

## REFERENCES

1. Kim SK, Kim HS. Secondary Asian rhinoplasty: Lengthening the short nose. *Aesthet Surg J*. 2013;33:353–362.
2. Park JH, Jin HR. Use of autologous costal cartilage in Asian rhinoplasty. *Plast Reconstr Surg*. 2012;130:1338–1348.
3. Jung DH, Moon HJ, Choi SH, Lam SM. Secondary rhinoplasty of the Asian nose: Correction of the contracted nose. *Aesthetic Plast Surg*. 2004;28:1–7.
4. Suh MK, Ahn ES, Kim HR, Dhong ES. A 2-year follow-up of irradiated homologous costal cartilage used as a septal extension graft for the correction of contracted nose in Asians. *Ann Plast Surg*. 2013;71:45–49.
5. Kridel RW, Ashoori F, Liu ES, Hart CG. Long-term use and follow-up of irradiated homologous costal cartilage grafts in the nose. *Arch Facial Plast Surg*. 2009;11:378–394.

6. Moseley TA, Zhu M, Hedrick MH. Adipose-derived stem and progenitor cells as fillers in plastic and reconstructive surgery. *Plast Reconstr Surg*. 2006;118(Suppl):121S–128S.
7. Gimble J, Guilak F. Adipose-derived adult stem cells: Isolation, characterization, and differentiation potential. *Cytotherapy* 2003;5:362–369.
8. Rodbell M. Metabolism of isolated fat cells: I. Effects of hormones on glucose metabolism and lipolysis. *J Biol Chem*. 1964;239:375–380.
9. Rohrich RJ, Hoxworth RE, Thornton JF, Pessa JE. The pyriform ligament. *Plast Reconstr Surg*. 2008;121:277–281.
10. Toriumi DM, Bared A. Revision of the surgically overshortened nose. *Facial Plast Surg*. 2012;28:407–416.
11. Gunter JP, Clark CP, Friedman RM. Internal stabilization of autogenous rib cartilage grafts in rhinoplasty: A barrier to cartilage warping. *Plast Reconstr Surg*. 1997;100:161–169.
12. Kim HK, Rhee SC. Augmentation rhinoplasty using a folded “pure” dermal graft. *J Craniofac Surg*. 2013;24:1758–1762.
13. Nakakita N, Sezaki K, Yamazaki Y, Uchinuma E. Augmentation rhinoplasty using an L-shaped auricular cartilage framework combined with dermal fat graft for cleft lip nose. *Aesthetic Plast Surg*. 1999;23:107–112.
14. Constantine FC, Lee MR, Sinno S, Thornton JF. Reconstruction of the nasal soft triangle subunit. *Plast Reconstr Surg*. 2013;131:1045–1050.
15. Gir P, Oni G, Brown SA, Mojallal A, Rohrich RJ. Human adipose stem cells: Current clinical applications. *Plast Reconstr Surg*. 2012;129:1277–1290.
16. Kim M, Kim I, Lee SK, Bang SI, Lim SY. Clinical trial of autologous differentiated adipocytes from stem cells derived from human adipose tissue. *Dermatol Surg*. 2011;37:750–759.
17. Choi J, Minn KW, Chang H. The efficacy and safety of platelet-rich plasma and adipose-derived stem cells: An update. *Arch Plast Surg*. 2012;39:585–592.
18. Sung HM, Suh IS, Lee HB, Tak KS, Moon KM, Jung MS. Case reports of adipose-derived stem cell therapy for nasal skin necrosis after filler injection. *Arch Plast Surg*. 2012;39:51–54.
19. Lee BJ, Wang SG, Lee JC, et al. The prevention of vocal fold scarring using autologous adipose tissue-derived stromal cells. *Cells Tissues Organs* 2006;184:198–204.
20. Madonna R, Delli Pizzi S, Di Donato L, et al. Non-invasive in vivo detection of peripheral limb ischemia improvement in the rat after adipose tissue-derived stromal cell transplantation. *Circ J*. 2012;76:1517–1525.
21. Kim JH, Jung M, Kim HS, Kim YM, Choi EH. Adipose-derived stem cells as a new therapeutic modality for ageing skin. *Exp Dermatol*. 2011;20:383–387.
22. Kim Y, Kim H, Cho H, Bae Y, Suh K, Jung J. Direct comparison of human mesenchymal stem cells derived from adipose tissues and bone marrow in mediating neovascularization in response to vascular ischemia. *Cell Physiol Biochem*. 2007;20:867–876.
23. Lee WY, Park KJ, Cho YB, et al. Autologous adipose tissue-derived stem cells treatment demonstrated favorable and sustainable therapeutic effect for Crohn’s fistula. *Stem Cells* 2013;31:2575–2581.
24. Toriumi DM. New concepts in nasal tip contouring. *Arch Facial Plast Surg*. 2006;8:156–185.